

Cerebral Blood Flow Imaging with 3D GRASE ASL Sequence Increases SNR and Shortens Acquisition Time

David A. Feinberg^{1,2,3}; Matthias Günther^{1,4,5}

¹Advanced MRI Technologies, LLC, Sebastopol, CA, USA

²University of California, Berkeley and San Francisco, CA, USA

³Redwood Regional Medical Group, Santa Rosa, CA, USA

⁴mediri GmbH, Heidelberg, Germany

⁵University Hospital Mannheim, Neurology, Heidelberg, Germany

Abstract

Arterial Spin Labeling (ASL) is a technique capable of measuring cerebral blood flow (CBF) in humans. However, ASL is limited by low sensitivity given blood is ~3% by volume in brain parenchyma. Single-shot 3D GRASE ASL technique has made possible whole brain coverage with over twice the signal-to-noise ratio (SNR) of 2D EPI ASL. To achieve even higher spatial resolution in fast acquisitions, a segmented version of the 3D GRASE ASL sequence is combined with a 32-channel coil at 3 Tesla to achieve 128 and 256 matrix images in 1 to 2 minutes.

Introduction

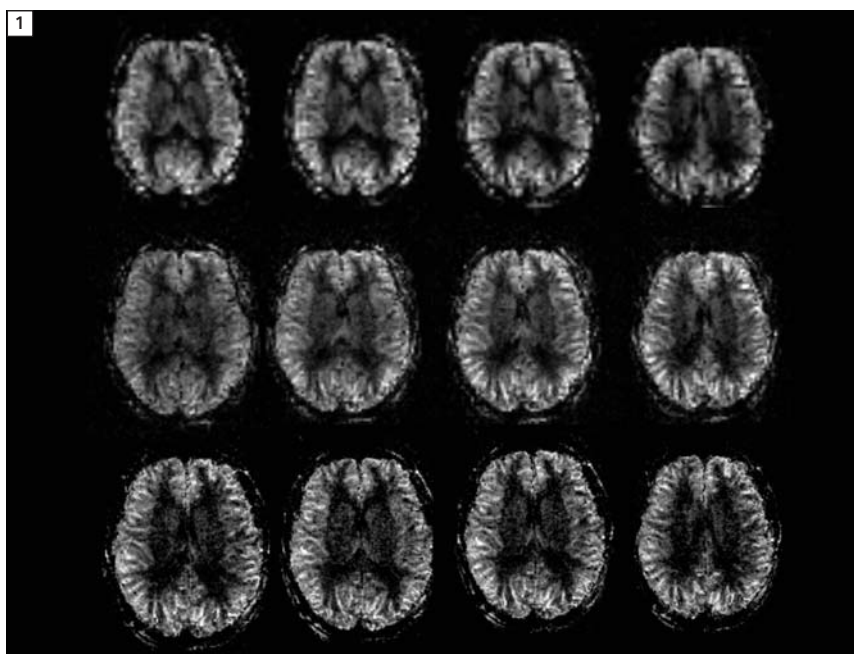
In the early 1980s when the very first MRI blood flow images were shown at conferences, Nobel Prize laureate Prof. Paul Lauterbur commented, "As MR imaging techniques develop, blood flow imaging will advance with them." This is fortelling of the recent developments describing the uniquely powerful Arterial Spin Labeling (ASL) method of blood flow imaging [1–6], since it is very flexible and can be adapted to several different MR imaging sequences. Each imaging technique differs in speed, image quality and ability to quantify blood flow. To be discussed below are the advantages of 3D sequences [1, 2, 26, 27] compared to 2D MRI in overcoming physiologic limitations in obtaining

whole brain coverage. The 3D gradient and spin echo (GRASE) [1, 2, 18] read-out scheme has advantages of refocusing many more signals than RARE / TSE / FSE or EPI sequences for higher SNR which translates into greatly reduced imaging time and much higher spatial resolution (Fig. 1). It has additional advantages of reduced susceptibility arti-

facts compared to Spiral and EPI techniques for improved image quality. Several examples of 3D GRASE ASL are presented here along with a fuller discussion of these differences.

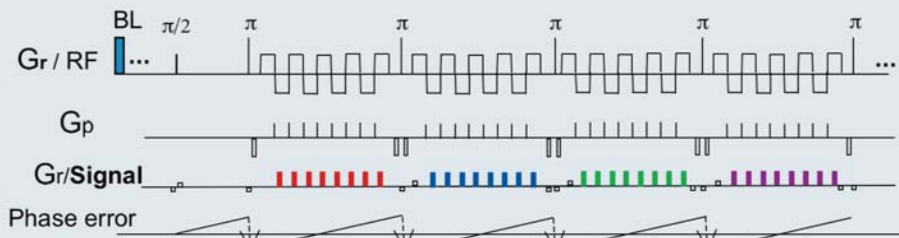
What is ASL imaging?

To measure blood perfusion in brain tissue, it is necessary to quantify signal



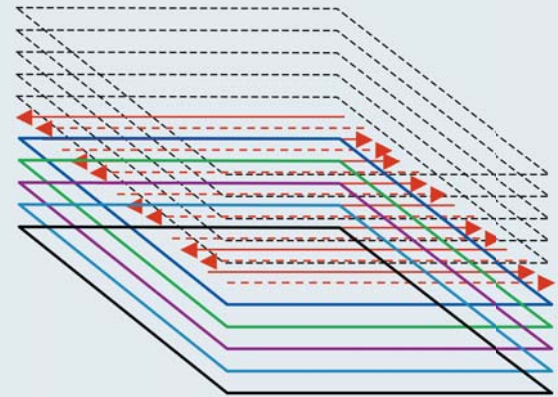
1 3D GRASE ASL with 32-channel coil **row 1**) 64 matrix, resolution $4 \times 4 \times 4 \text{ mm}^3$ voxel, 26 images, 16 s, **row 2**) 128 matrix, resolution $2.5 \times 2.5 \times 2.0 \text{ mm}^3$ in 1 min **row 3**) 256 matrix, resolution $1.5 \times 1.5 \times 3.0 \text{ mm}^3$, 26 images, 2:04 min.

2A



3D GRASE ASL

2B



2 3D GRASE ASL. The 180° RF refocusing pulses (π) prevent large phase error. EPI type gradient refocusing (Gr) gives maximum number of signals, (BL) blood labeling and background suppression pulses.

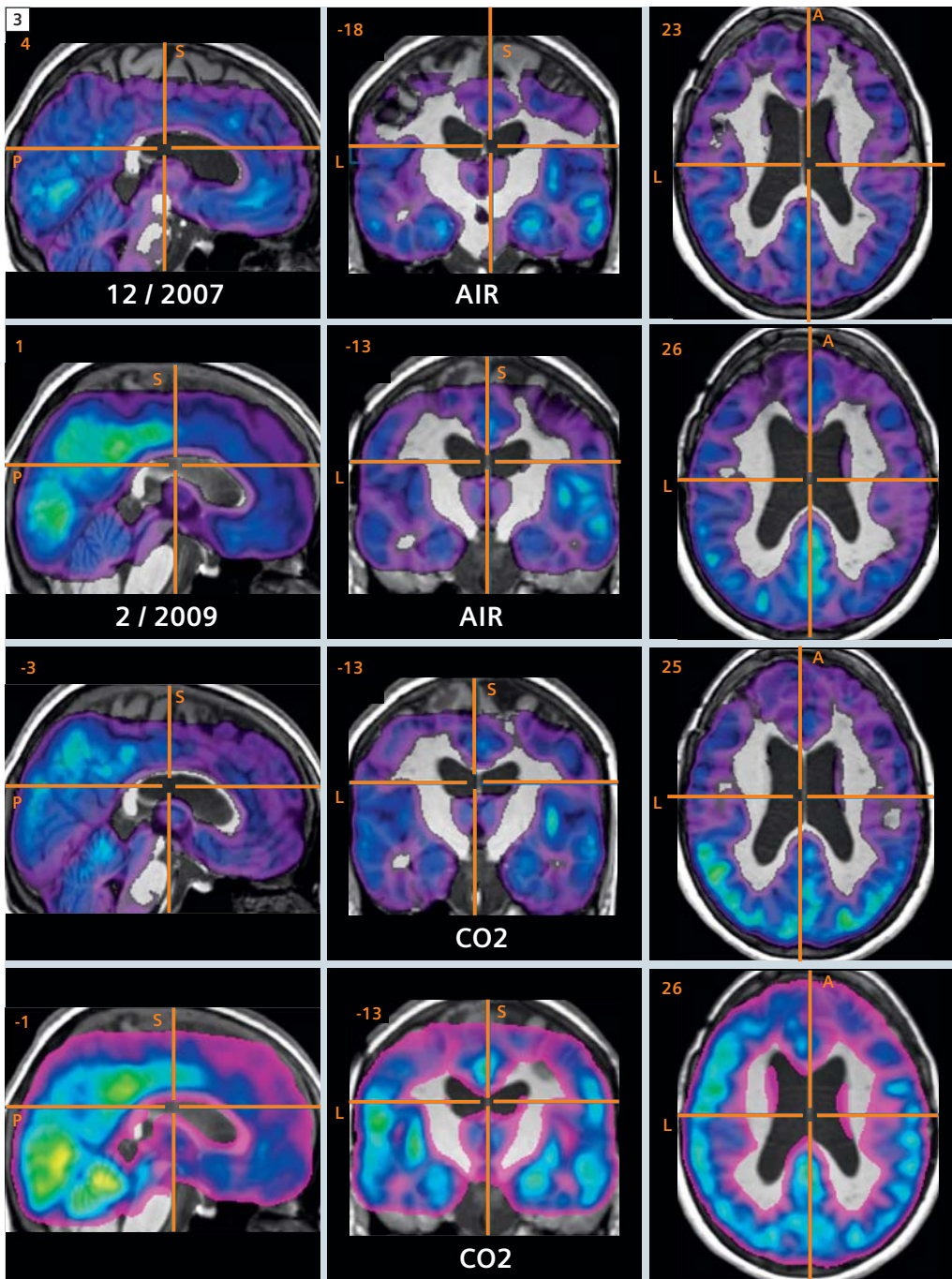
changes independent of the signal from the partial volumed static brain tissue. ASL obtains two images, each with identical signals from brain tissue but different blood signal as affected by the presence / absence of blood labeling RF pulses (typically inversion RF pulses). Ideally, subtraction of the two images removes static brain tissue signal leaving only blood signal which intensity reflects hemodynamic parameters of cerebral blood flow (CBF) and the blood bolus arrival time (BAT) to the tissue. Critical to the success of ASL, the blood spin labeling is achieved by manipulating the longitudinal magnetization, which stores the "labeled" (tagged) spin magnetization with T1 decay (~1200–1500 ms) rather than with shorter T2 decay (~150 ms). The longer T1 decay enables enough time for the spins in blood to reach the brain tissue upstream from the arterial location of labeling. The tagging of the inflowing blood spins can either occur in a small localized region but over a long period of time of several seconds (continuous ASL [2, 3, 7, 9, 14, 24]) or at a larger region at a defined point in time (pulsed ASL [28–31]). After labeling

preparation the tagged blood spins are given an inflow time TI to allow them to move into the microvasculature of the imaging region. A typical inflow time is 1500 ms. The beginning of the image readout sequence typically occurs with a 90° excitation pulse followed by either a gradient echo train sequence such as EPI or spiral, where the signal decays with T2* or by a spin echo based sequence like RARE or GRASE, where the signal decays with a combination of T2 and a component of stimulated echoes with longer T1 decay. As mentioned above, the measured signal will be dominated by brain tissue signal with blood signal being in the range of a few percent. Therefore, additional application of background suppression pulse schemes are incorporated to reduce the amplitude of static signal so errors in net subtracted signal is reduced for more reliable measurement of blood signal [32]. For quantification of cerebral blood flow several models exist [6, 12, 13] with the one-compartment model [12] being used most often. One of the most critical aspects of quantification is the variation of arrival times of the labeled blood bolus

at different regions of the brain. Several techniques have been developed to reduce the sensitivity to this bolus arrival time (BAT) [4, 6]. Time-consuming sampling the inflow of the labeled blood into the tissue allows the measurement of BAT as an additional hemodynamical parameter. For whole brain application, this technique requires an efficient ASL technique, which provides sufficient SNR to reduce overall scan time and supports large region coverage.

2D and 3D ASL slice coverage limitations of hemodynamic timing

One of the major drawbacks of 2D EPI based ASL is a limitation on the number of images, preventing whole brain coverage. The EPI images are readout sequentially. With the acquisition of each EPI image ~50 msec, the blood inflow time of each slice increases with this time increment until the net range of inflow time is too large to ensure that the labeled blood is in the same vascular compartment in all slices. The 3D MRI sequences entirely overcome this problem because all images are readout



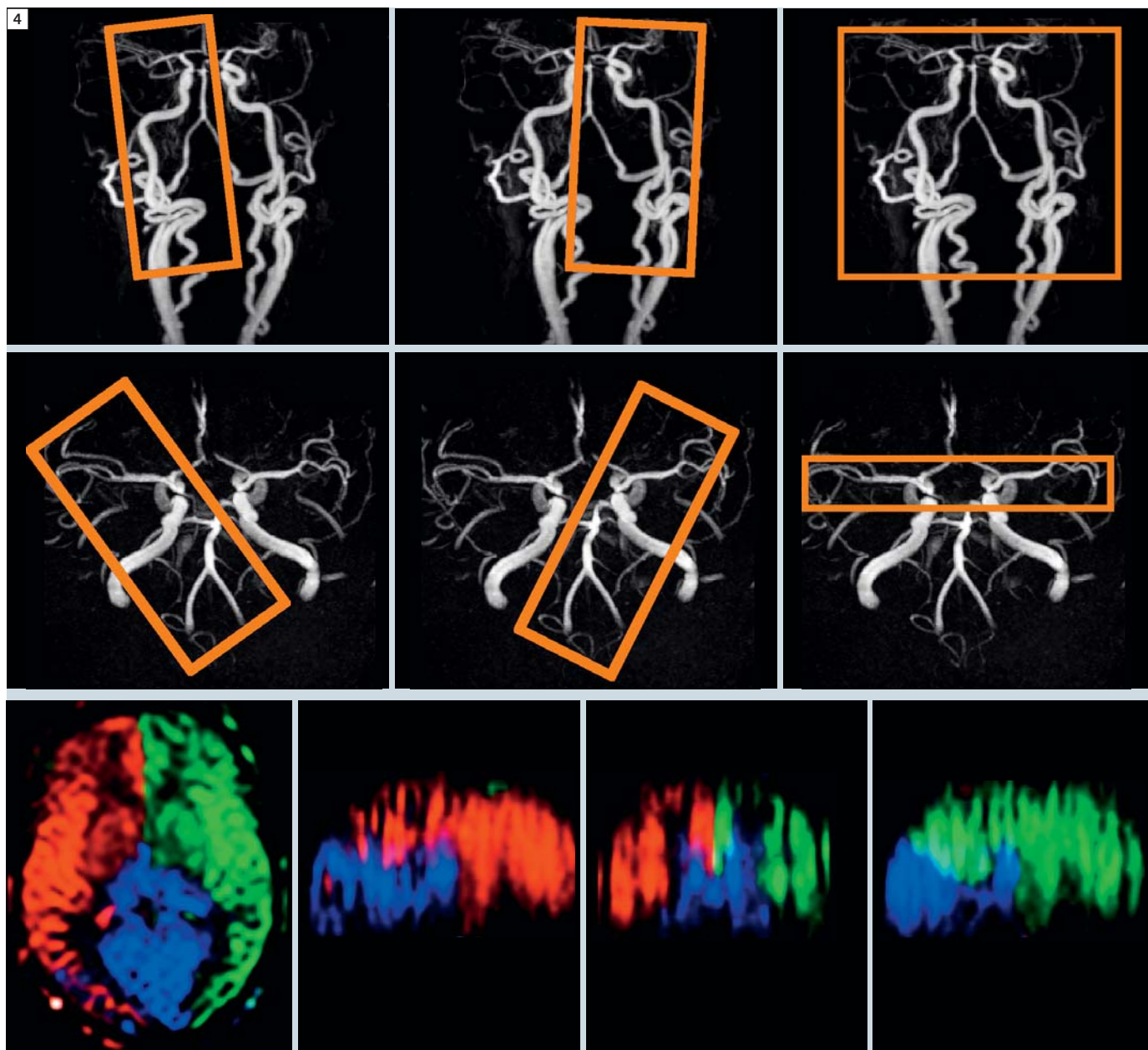
3 CBF maps of MoyaMoya patient. Rows 1 and 2: control image while breathing air. Rows 3 and 4: hypercapnia, CO₂ challenge. Rows 1 and 3: 12/2007 pre-surgery. Rows 2 and 4: 2/2009 post-surgery show greater vascular reactivity post-surgery. The CBF maps from 3D GRASE ASL overlaid on anatomic images. (Courtesy of Rik Achten, GifMI, UGent, Belgium.)

simultaneously rather than in temporal sequential order. The spins move into the brain tissue and at a specified time, all slices are encoded simultaneously beginning with a single 90 degree pulse covering a thick slab 3D volume [1, 27], not a single slice [11]. The echo train reads out all slices together which are then separated by a 3D Fourier Trans-

form, which has additional \sqrt{N} advantage of higher SNR compared to 2D EPI. Similarly, in a 3D readout the inversion pulse timing for background suppression is optimal for all slices, while in sequential 2D imaging there is variation between slices in the effectiveness of background suppression [32].

Artifacts in 3D GRASE compared to RARE, Spiral, EPI

Basically any echo train sequence can be used for 3D ASL readout but each differs in their number of echoes, accumulative phase errors causing susceptibility artifacts, and SNR efficiency [25, 17]. Echo volume imaging (EVI) is the 3D variant of EPI which has an echo train time lim-

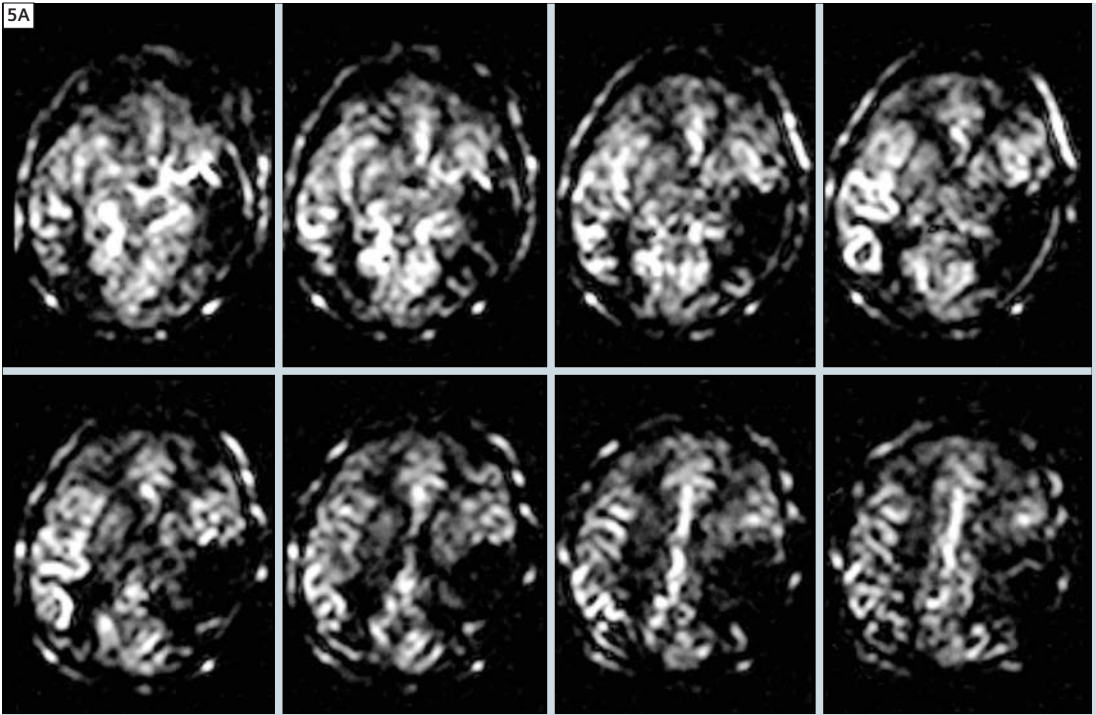


4 Color-coded visualization of vascular territories in transverse, sagittal and coronal orientation. Three excitation regions shown in MRA (yellow box) A-P (top) and C-C (middle).

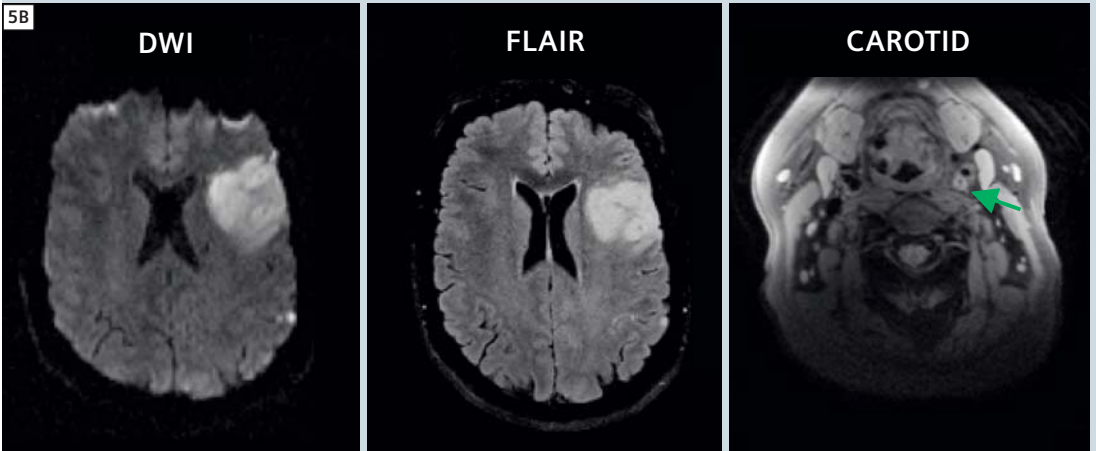
ited to under ~80 ms due to rapid T2* decay and it has large phase errors leading to susceptibility artifacts with regions of signal loss (similar to spiral and rectilinear EPI). 3D GRASE sequences has many RF refocusing pulses which maintains a low level of phase error and permits a sustainable echo train for up to 300 ms. RARE / TSE has similar net

sequence time, however, there is a large fraction of time spent on RF refocusing pulses, 1 per signal. GRASE uses switched gradient rephrasing of signals to produce several times as many signals as TSE, which translates into faster imaging time and higher SNR per imaging time. A similar and useful variant, Spiral RARE (or Spiral GRASE) also has efficiency

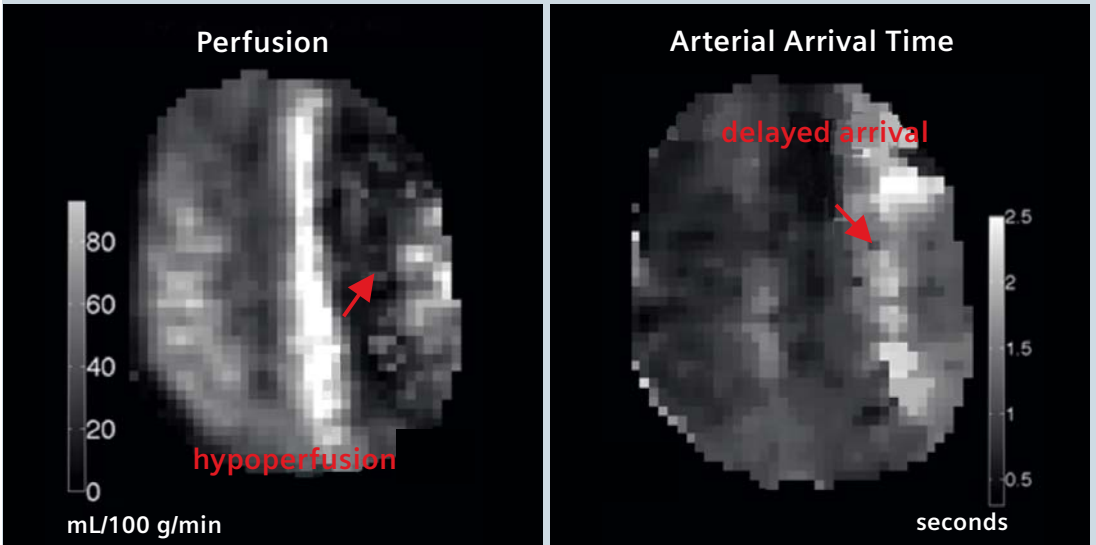
advantages, however, it places the beginning of the spiral, the center of k-space, on a gradient echo position at the beginning of each time interval between RF pulses, increasing susceptibility weighting. Furthermore, non-Cartesian image reconstruction methods are required. The key to success of 3D GRASE has been its high SNR, low arti-

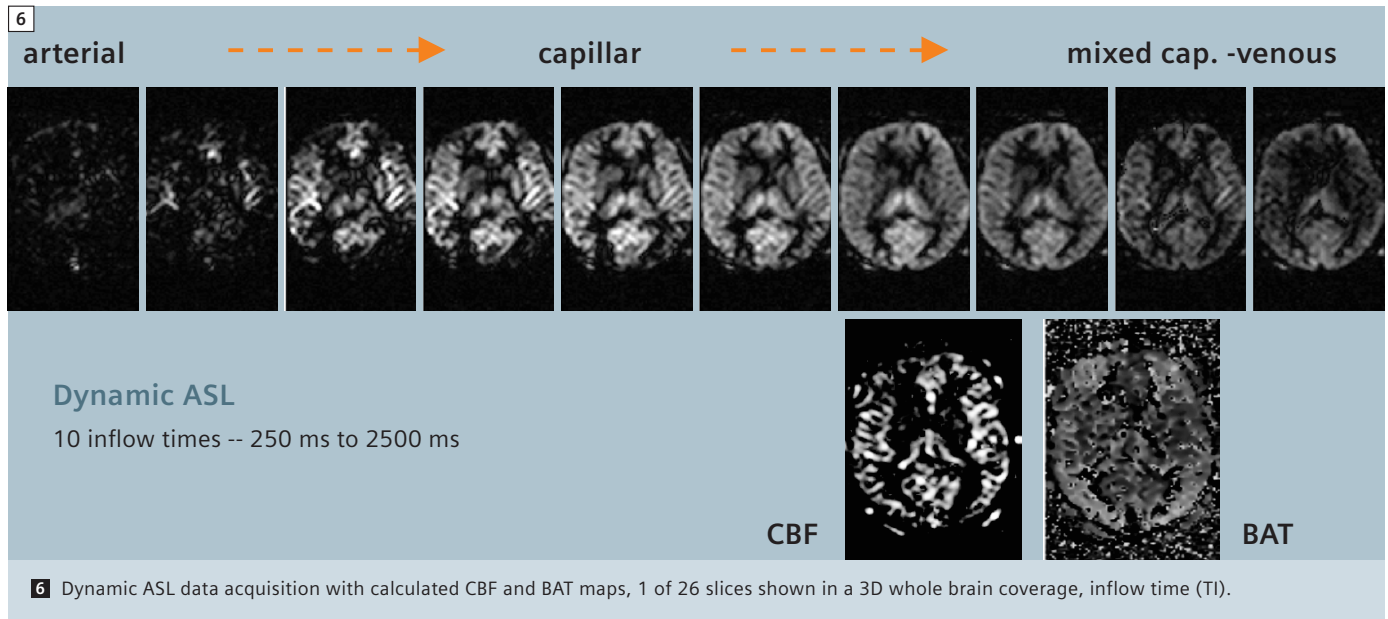


5 Single-shot 3D ASL of two patients with acute stroke. A: in left MCA territory,



5B In second patient (48 hour) with hypoperfusion and delayed bolus arrival time (BAT) (red arrows) in ischaemic hemisphere, MRA reveals a near 100% occlusion in the left ICA (yellow arrow). (Reproduced with permission of: BJ MacIntosh, P Jeppard et al., ISMRM 2009).





fact load due to the CPMG (Carr-Purcell-Meiboom-Gill echos) timing, and whole brain coverage made possible with the simplified physiological timing in 3D acquisitions.

The source of high SNR and fast data acquisition of 3D GRASE

The number of echoes produced in a single echo train of EPI, TSE and GRASE is dependent on the rate of echo refocusing which is relatively slow in RF refocusing (~4 ms) versus fast with switched gradient refocusing (~0.2 ms). It is no less dependent upon the signal decay times of T2 and T1 stimulated echo compared to shorter T2* of EPI. In relative terms the number of refocused echoes is in EPI (2 signal / ms x 30 ms) 60 echoes, TSE (1 signal / 3 ms x 300 ms) 100 echoes, and 3D GRASE (1.5 signal / ms x 300 ms) 450 echoes. Therefore, EPI has the fastest rate of echo generation by means of gradient switching but the shortest 'echo train time', ETT, due to T2* decay. TSE has the slowest rate using RF refocusing but a long ETT, whereas 3D GRASE has the benefit of both a fast refocusing rate and a long ETT which are multiplicative for much higher net signal (Fig. 2). In addition to

increasing spatial resolution and image speed, the image SNR is dependent on square root of N signals in the Fourier transform. Therefore, the relative SNR of EPI, TSE and 3D GRASE is $\sqrt{60}$, $\sqrt{100}$ and $\sqrt{450}$, 7.7, 10.0 and 21.2 respectively. The possible earlier TE of EPI to a lesser extent mitigates some of this large SNR disadvantage to 3D GRASE, which nets to nearly a factor of 2.5 higher SNR and, thus, 3D GRASE has a factor of 6–8 in scan time reduction (fewer signal averages) at constant SNR.

32-channel RF head coil effects speed and resolution

Utilizing a 32-channel coil yields another ~2 higher SNR in cortical brain regions for all imaging techniques, and these SNR gains are multiplied in 3D GRASE. This allows either extremely fast ASL acquisitions or higher resolution than previously achieved in ASL images at 3 Tesla [25] (Fig. 1).

The 32-channel coil has therefore been used to acquire larger matrix images with higher resolutions, with up to 256 matrix in reasonable scan times of 2 minutes. Instead of going to higher resolution, the reduced acquisition time can be used to sample variable inflow times to separately quantify CBF from bolus

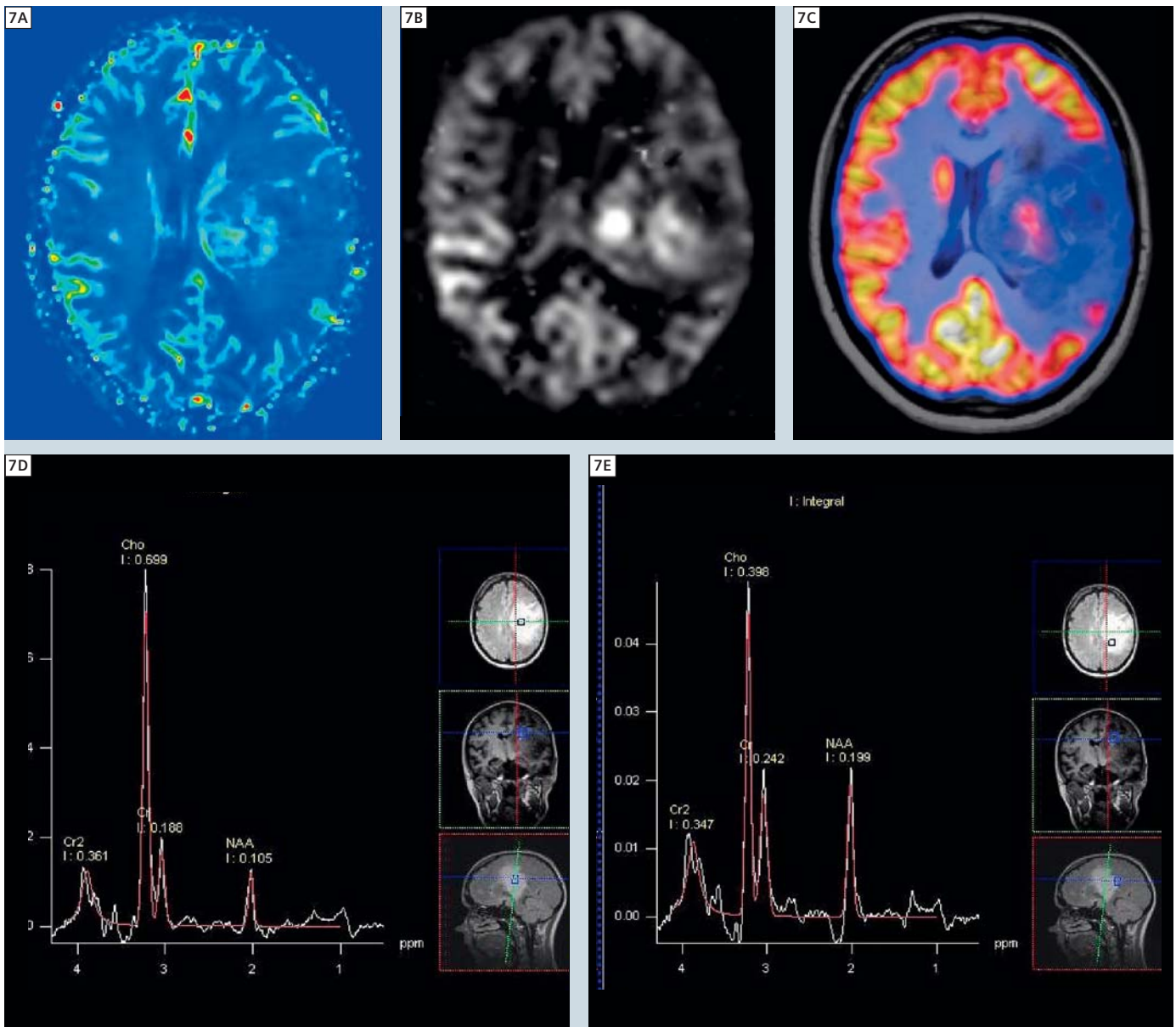
arrival time BAT using parametric curve fitting (Fig. 6). It should be noted that 3D GRASE can be combined with several different ASL encoding schemes [22, 24].

Resolving vascular territories in the brain

The images can be performed with separation of vascular territories by labeling different downstream vessels separately, (Fig. 4). Hadamard encoding has permitted to incorporate vascular territory sensitivity into an ASL protocol without loss of SNR compared to non-selective (standard) ASL to keep scan times in an acceptable range for clinical applications [21]. Stroke patients may be studied with 3D vascular territory ASL to evaluate changes occurring during recovery or to assess therapies (23). Patients with arterio-venous malformations (AVM) or aneurysms can have altered flow circuitry in the circle of Willis and downstream cerebral arteries identifiable as changes in vascular territory perfusion [20].

High spatial resolution ASL

The segmented sequence version of 3D GRASE ASL provides shorter RF pulse intervals in the CPMG spin echo sequence [27]. This reduces susceptibility artifact and concurrently shortens the time of



7 ASL perfusion of Glioma. **A:** Dynamic susceptibility contrast, increased perfusion in center of a recurrent Glioma, originally grade II, **B:** ASL CBF map from dynamic ASL, showing increased perfusion **C:** PET image fused to MRI. A biopsy was performed in the location of highest perfusion in ASL CBF and a grade III was diagnosed. **D, E:** At time of biopsy, MRS showed the Cho/Cr was highest in biopsy location. (Courtesy of Rik Achten, GIfMI, UGent, Belgium.)

each of several echo trains for reduced through-plane blurring compared to the single-shot sequences. Image distortions were also reduced using the 128 matrix instead of 64 matrix as the larger FOV allowed swapping the phase and read axes, placing the highly switched read axis onto the head's lateral axis with less physiologic stimulation to allow higher bandwidth and closer echo spacing for

less distortions. One unexpected fortuitous finding is that the segmented 3D GRASE sequence does not have artifacts from CSF or brain motion and the labeling pulses normalizes blood inflow and the larger 3D volume further removes slice inflow artifacts. The SNR gains from the 32-channel coil/receiver system enabled higher resolution ASL images. The ASL encoding used

pulsed ASL (PASL) sequence with QUIPSS II (QUantitativ Imaging of Perfusion using a Single Subtraction) variants and background suppression pulses, previously described [1]. One can incorporate the 3D ASL sequence into a clinical protocol, requiring only 8–16 second scan time for whole brain coverage at 4 mm isotropic resolution or 2–4 minutes to

obtain highly quantitative BAT and CBF maps (Fig. 6), useful for evaluation of therapeutic responses to drugs and surgical interventions (Fig. 3), following brain recovery after stroke (Fig. 5), or evaluation of tumors (Fig. 7). In conclusion, with ASL scan times now reduced from ~15 minutes 6 years ago, to ~16 seconds for a whole brain slice coverage, perfusion images should become just another image contrast mechanism, utilized in all routine clinical screening brain studies. With such fast scans and no need for contrast agents, ASL based perfusion imaging is an important new contrast mechanism that may be used by the radiologist in all routine clinical brain screening studies. Already with these refinements, ASL is faster than CT perfusion contrast imaging, and avoids x-ray dosage and risks of iodinated contrast agent to the patient. The rapid automated image processing of ASL perfusion maps enables their practical use in emergency medical studies. The ability of MRI to rapidly show several different contrast mechanisms in images (T1-weighted, FLAIR, diffusion-weighted imaging (*syngo* DWI)) and now CBF from 3D ASL without contrast injections, further establishes MRI as an invaluable diagnostic examination of brain disease.

Acknowledgment: N.I.H. National Inst. Neurological Disease and Stroke: grant no. 5R44NS059223

References

- 1 Gunther, M., K. Oshio, and D.A. Feinberg, Single-shot 3D imaging techniques improve arterial spin labeling perfusion measurements. *Magn Reson Med*, 2005. 54(2): p. 491–8.
- 2 M. A. Fernandez-Seara, Z.W., J. Wang, M. Korczykowski, M. Guenther, D. Feinberg, J. A. Detre. 3T Pseudo-continuous ASL Perfusion fMRI with Background-Suppressed Single Shot 3D GRASE During Memory Encoding. in *International Society for Magnetic Resonance in Medicine*. 2006. Seattle.
- 3 Detre, J.A., et al., Perfusion imaging. *Magn. Reson. Med.*, 1992. 23: p. 37–45.
- 4 Alsop, D.C. and J.A. Detre, Reduced transit-time sensitivity in noninvasive magnetic resonance imaging of human cerebral blood flow. *J. Cereb. Blood Flow Metab.*, 1996. 16: p. 1236–1249.
- 5 Gonzalez-At, J.B., D.C. Alsop, and J.A. Detre, Perfusion and transit time changes during task activation determined with steady-state arterial spin labeling. *Magn. Reson. Med.*, 2000. 43: p. 739–46.
- 6 Wong, E.C., R.B. Buxton, and L.R. Frank, Quantitative imaging of perfusion using a single subtraction (QUIPSS and QUIPSS II). *Magn Reson Med*, 1998. 39: p. 702–8.
- 7 Yang, Y., et al., Transit time, trailing time, and cerebral blood flow during brain activation: measurement using multislice, pulsed spin-labeling perfusion imaging. *Magn Reson Med*, 2000. 44(5): p. 680–5.
- 8 Ye, F.Q., et al., Correction for vascular artifacts in cerebral blood flow values measured using arterial spin tagging techniques. *Magn. Reson. Med*, 1997. 37: p. 226–35.
- 9 Alsop, D.C. and J.A. Detre, Multisection cerebral blood flow MR imaging with continuous arterial spin labeling. *Radiology*, 1998. 208: p. 410–16.
- 10 McLaughlin, A.C., et al., Effect of magnetization transfer on the measurement of cerebral blood flow using steady-state arterial spin tagging approaches: a theoretical investigation. *Magn Reson Med*, 1997. 37(4): p. 501–10.
- 11 Wang, J., et al., Comparison of quantitative perfusion imaging using arterial spin labeling at 1.5 and 4.0 Tesla. *Magn Reson Med*, 2002. 48(2): p. 242–54.
- 12 Wong, E.C., R.B. Buxton, and L.R. Frank, A theoretical and experimental comparison of continuous and pulsed arterial spin labeling techniques for quantitative perfusion imaging. *Magn. Reson. Med.*, 1998. 40: p. 348–55.
- 13 Buxton, R.B., et al., A general kinetic model for quantitative perfusion imaging with arterial spin labeling. *Magn Reson Med*, 1998. 40(3): p. 383–96.
- 14 Williams, D.S., et al., Magnetic resonance imaging of perfusion in the isolated rat heart using spin inversion of arterial water. *Magn Reson Med*, 1993. 30(3): p. 361–5.
- 15 Wang, J., et al., Empirical analyses of null-hypothesis perfusion fMRI data at 1.5 and 4 T. *Neuroimage*, 2003. 19(4): p. 1449–62.
- 16 Feinberg, D.A. and K. Oshio, GRASE (gradient and spin-echo) MR imaging: a new fast clinical imaging technique. *Radiology*, 1991. 181(2): p. 597–602.
- 17 Feinberg, D.A., B. Kiefer, and G. Johnson, GRASE improves spatial resolution in single shot imaging. *Magn Reson Med*, 1995. 33(4): p. 529–33.
- 18 Feinberg DA, Kiefer B, Litt AW. High resolution GRASE MRI of the brain and spine: 512 and 1024 matrix imaging. *J Comput Assist Tomogr*. 1995 Jan-Feb;19(1):1–7.
- 19 Luh, W.M., et al., QUIPSS II with thin-slice T1 periodic saturation: a method for improving accuracy of quantitative perfusion imaging using pulsed arterial spin labeling. *Magn Reson Med*, 1999. 41(6): p. 1246–54.
- 20 Sallustio F, Kern R, Günther M, Szabo K, Griebel M, Meairs S, Hennerici M, Gass A. Assessment of intracranial collateral flow by using dynamic arterial spin labeling MRA and transcranial color-coded duplex ultrasound. *Stroke*. 2008 Jun;39(6):1894–7. Epub 2008 Apr 10.
- 21 Günther M. Efficient visualization of vascular territories in the human brain by cycled arterial spin labeling MRI. *Magn Reson Med*. 2006 Sep;56(3):671–5.
- 22 Fernández-Seara MA, Edlow BL, Hoang A, Wang J, Feinberg DA, Detre JA. Minimizing acquisition time of arterial spin labeling at 3T. *Magn Reson Med*. 2008 Jun;59(6):1467–71.
- 23 MacIntosh BJ, Pattinson KT, Gallichan D, Ahmad I, Miller KL, Feinberg DA, Wise RG, Jezzard P. Measuring the effects of remifentanyl on cerebral blood flow and arterial arrival time using 3D GRASE MRI with pulsed arterial spin labelling. *J Cereb Blood Flow Metab*. 2008 Aug;28(8):1514–22. Epub 2008 May 28.
- 24 Fernández-Seara MA, Wang Z, Wang J, Rao HY, Guenther M, Feinberg DA, Detre JA. Continuous arterial spin labeling perfusion measurements using single shot 3D GRASE at 3 T. *Magn Reson Med*. 2005 Nov;54(5):1241–7.
- 25 McKinstry RC, Feinberg DA. Ultrafast magnetic resonance imaging. A new window on brain research. *Science*. 1998 Mar 20;279(5358):1965–6. No abstract available.
- 26 Feinberg DA, Ramanna S, Gunther M, Evaluation of new ASL 3D GRASE sequences using Parallel Imaging, Segmented and Interleaved k-space at 3T with 12- and 32-Channel coils. *ISMRM, Honolulu*, 2009
- 27 Talagala SL, Ye FQ, Ledden PJ, Chesnick S. Whole-Brain 3D Perfusion MRI at 3.0 T using CASL with a separate labeling Coil. *Mag Res Med*, 52: 131–140 (2004)
- 28 Edelman, R. R., B. Siewert, et al. (1994). "Signal targeting with alternating radiofrequency (STAR) sequences: application to MR angiography." *Magn Reson Med* 31(2): 233–8
- 29 Kwong, K. K., D. A. Chesler, et al. (1995). "MR perfusion studies with T1-weighted echo planar imaging." *Magn Reson Med* 34(6): 878–87.
- 30 Luh, W. M., E. C. Wong, et al. (1999). "QUIPSS II with thin-slice T1 periodic saturation: a method for improving accuracy of quantitative perfusion imaging using pulsed arterial spin labeling." *Magn Reson Med* 41(6): 1246–54.
- 31 Wong, E. C., R. B. Buxton, et al. (1998). "Quantitative imaging of perfusion using a single subtraction (QUIPSS and QUIPSS II)." *Magn Reson Med* 39(5): 702–8.
- 32 Ye, F. Q., J. A. Frank, et al. (2000). "Noise reduction in 3D perfusion imaging by attenuating the static signal in arterial spin tagging (ASSIST)." *Magn Reson Med* 44(1): 92–100.

Contact

David Feinberg, M.D., Ph.D.
Advanced MRI Technologies
652 Petaluma Ave.,
J Sebastopol, CA, 95472
USA
david.feinberg@advancedmri.com