

Extracellular gadolinium-based contrast media: An overview

Marie-France Bellin*, Aart J. Van Der Molen

University Paris-Sud 11, Department of Radiology, University Hospital Paul-Brousse, AP-HP, 12,
Avenue Paul Vaillant-Couturier, 94804 Villejuif Cedex, France

Received 4 January 2008; received in revised form 4 January 2008; accepted 8 January 2008

Abstract

Increasing use is made of extracellular MRI contrast agents that alter the image contrast following intravenous administration; they predominantly shorten the T1 relaxation time of tissues. The degree and location of these changes provide substantial diagnostic information. However gadolinium-based contrast agents (Gd-CA) are not inert drugs. They may cause acute non-renal adverse reactions (e.g. anaphylactoid reactions), acute renal adverse reactions (e.g. contrast induced nephropathy), delayed adverse reactions (nephrogenic systemic fibrosis) and problems at the site of injection (e.g. local necrosis). This review describes the current status of Gd-CA, their mechanism of action, chemical structure, pharmacokinetics, dosage, elimination, nephrotoxicity and adverse events.

© 2008 Elsevier Ireland Ltd. All rights reserved.

Keywords: Contrast agents; Gadolinium; Osmolality; Nephrotoxicity; Adverse reactions

Extracellular gadolinium-based contrast agents (Gd-CA) are the most widely used contrast agents for MR imaging. Currently it is estimated that 40–50% of all MR studies performed worldwide are contrast-enhanced [1] and the degree of contrast utilization is expected to increase in the future [2]. Gd-CA are considered to have an excellent overall safety profile. However, both renal and non-renal adverse reactions have been reported in the last few years [3–11] following administration to patients with underlying kidney disease. Several recent reports have associated intravenous administration of Gd-CA with nephrogenic systemic fibrosis (NSF), a rare, relatively new, devastating fibrosing disorder of the skin and other systemic organ, such as the liver, lungs, muscles and heart [4,9,12,13]. This disease has been reported exclusively in patients with renal insufficiency and is strongly associated with prior exposure to Gd-CA. At the time of this writing, the great majority (>90%) of published cases have been associated with the use of gadodiamide (Omniscan[®], GE Healthcare, Chalfont St. Giles, United Kingdom) and to a much lesser degree of gadopentetate (Magnevist[®], Bayer Schering, Berlin, Germany) and gadoversetamide (OptiMARK[®], Covidien, St. Louis, USA) in the USA (for further information please refer to the other papers in this issue of European Journal of Radiology on NSF). It is the radiologist's responsibility to understand

the potential adverse effects of gadolinium chelates, to identify the special situations associated with a higher risk of occurrence, and to justify the use of Gd-CA. The purpose of this review is to discuss the chemical structure and the mechanism of action of Gd-CA, their dosage, elimination, and relevant aspects of their clinical pharmacology.

1. Toxicology of gadolinium

All available Gd-CA are chelates that contain the gadolinium ion Gd³⁺. Gadolinium belongs to the lanthanide group of elements. Free gadolinium is highly toxic. Its ionic radius (107.8 pm) is close to that of Ca²⁺ (114 pm). Free gadolinium is an inorganic blocker of many types of voltage-gated calcium channels at nano- to micro-molar concentrations [14]. It inhibits the physiological processes which depend upon Ca²⁺ influx as well as the activity of some enzymes. It may also depress the reticuloendothelial system [15] and has been found to increase the expression of hepatic cytokines. Chelation of gadolinium by appropriate ligands dramatically reduces its acute toxicity.

2. Chemical structure

To date, nine intravenous Gd-CA have been approved, among which eight have been approved in Europe, and six in the United States (Table 1). Their generic names, brand names, acronyms and chemical characteristics are described

* Corresponding author. Tel.: +33 1 45 59 35 29; fax: +33 1 45 59 37 84.
E-mail addresses: marie-france.bellin@pbr.aphp.fr,
marie-france.bellin@u-psud.fr (M.-F. Bellin).

Table 1
Approval status of gadolinium (Gd) chelates in clinical use

Gd chelate (trade name)	Body region(s) approved	Approval	Approved doses (mmol/kg) for body imaging	Approved doses (mmol/kg) for CNS ^a imaging	Approved doses (mmol/kg) for MR angiography	Approved doses (mmol/kg) for children
Gadopentetate dimeglumine (Magnevist [®])	CNS ^a , whole body	USA, EU, Japan	0.1	0.1–0.2	0.1–0.3 ^b	0.1
Gadodiamide (Omniscan [®])	CNS ^a , whole body	USA, EU, Japan	0.1–0.3	0.1–0.3	0.1–0.3	From 6 months: 0.1
Gadoterate meglumine (Dotarem [®])	CNS ^a , whole body	EU	0.1	0.1–0.3	0.2	0.1
Gadoteridol (ProHance [®])	CNS ^a , whole body	USA, EU, Japan	0.1–0.3	0.1–0.3	Not approved	From 2 years and above: 0.1, 6 months–2 years: caution, <6 months: contraindicated
Gadobutrol (Gadovist [®])	CNS ^a	EU	Not approved	0.1–0.3	Not approved	Not approved
Gadobenate dimeglumine (MultiHance [®])	CNS ^a , liver	USA, EU	Liver: 0.05	0.1	Not approved	Not approved <18 years
Gadoversetamide (OptiMARK [®])	CNS ^a , liver	USA	0.1	0.1	Not approved	Not approved <18 years
Gadoxetic acid (Primovist [®]) (Europe), Eovist [®] (USA)	Liver	USA, EU	0.025 or 0.1 ml/kg	Not approved	Not approved	Not approved <18 years
Gadofosveset (Vasovist [®])	Abdominal and limb vessels	EU	Not approved	Not approved	MRA 0.03	Not approved <18 years

^a CNS: central nervous system.

^b Gadopentetate dimeglumine (Magnevist[®]) is approved for whole body imaging and for doses of 0.1–0.3 mmol/kg but does not have a trial based approval for MR angiography.

in Table 2. They include non-specific extracellular gadolinium chelates (gadopentetate, gadoterate, gadoteridol, gadodiamide, gadobutrol and gadoversetamide), two liver specific contrast agents (gadobenate and gadoxetate), and one contrast agent specifically designed for MR angiography (gadofosveset). After bolus injection, liver specific Gd-CA combine established features of extracellular contrast agents during the first minutes following injection with the advantages of hepatocyte specificity and biliary excretion in the delayed phase [16–18]. Gadofosveset, a new blood pool contrast agent designed for vascular imaging, is a gadolinium-based compound that binds reversibly to albumin in the blood [19]. This contrast agent gives both an increased signal intensity compared with that of other extracellular agents and persistent intravascular image enhancement for at least 1 h. Blood pool agents can provide dynamic images, such as those available with existing extracellular agents, and a longer steady-state phase to image the vasculature. The price is that the $T_{1/2}$ is much longer (18 h in patients with normal renal function) than that of the pure extracellular agent. Of course the excretion time is also longer in patients with reduced renal function. The advantage of the lower dose may be obviated by the much prolonged body exposure.

Extracellular Gd-CA are distributed within the extracellular interstitial space. They are formed by chelation of gadolinium to organic ligands. Chelation serves to eliminate heavy metal toxicity by preventing the cellular uptake of free gadolinium ion Gd^{3+} which has high toxicity. Chelation maintains the biodistribution of gadolinium chelates within the extracellular space and enhances renal filtration, resulting in a biological half life of approximately 1.5–2.0 h in patients with normal renal function. However in patients with renal kidney disease, renal elimination is decreased and delayed toxic effects of gadolinium may occur.

There are two structurally distinct categories of Gd-CA: the macrocyclic molecules where Gd^{3+} is caged in the preorganized cavity of the ligand and linear molecules (Fig. 1). The stability of extracellular contrast agents depends on their kinetic, thermodynamic and conditional stability. These parameters are not directly related to the molecular structure although macrocyclic contrast media have a much higher stability than linear (Table 2). The commercially available contrast agent with the lowest thermodynamic stability is the linear, non-ionic gadodiamide, which has been associated with the great majority of NSF reported cases. In addition, because of their relatively low stability, the pharmaceutical solutions of some gadolinium complexes (e.g. gadodiamide and gadoversetamide) include excess chelate to ensure the absence of toxic free Gd^{3+} cations in the pharmaceutical solutions over their shelf lives. Cyclic chelates need no excess chelate to ensure the absence of toxic Gd^{3+} in solution and are least likely to release free from the gadolinium complex through a process called transmetallation with endogenous ions from the body [13,14].

3. Stability of MRI contrast media

3.1. Transmetallation

Please refer to the chapter written by SK Morcos.

Table 2
Physicochemical characteristics of gadolinium-based MR contrast agents

Generic name	Gadopentetate dimeglumine	Gadoterate meglumine	Gadoteridol	Gadodiamide	Gadobutrol	Gadoversetamide	Gadobenate dimeglumine	Gadoxetic acid	Gadofosveset
Brand name	Magnevist®	Dotarem®	ProHance®	Omniscan®	Gadovist®	OptiMARK®	MultiHance®	Primovist®	Vasovist®
Acronym	Gd-DTPA	Gd-DOTA	Gd-HP-DO3A	Gd-DTPA-BMA	Gd-BT-DO3A	Gd-DTPA-BMEA	Gd-BOPTA	Gd-EOB-DTPA	Gd-DTPA
Manufacturer	Bayer	Guerbet	Bracco	GE Healthcare	Bayer	Tyco	Bracco	Bayer	Bayer
Characteristic	Schering Pharma	Schering Pharma	Schering Pharma	Schering Pharma	Schering Pharma	Schering Pharma	Schering Pharma	Schering Pharma	Schering Pharma
Molecular structure	0.5 mol/L	0.5 mol/L	0.5 mol/L	0.5 mol/L	0.5 mol/L	0.5 mol/L	0.5 mol/L	0.25 mol/L	0.25 mol/L
Charge	Linear	Cyclic	Cyclic	Linear	Cyclic	Linear	Linear	Linear	Linear
Thermodynamic stability constant (log K_{eq})	Ionic	Ionic	Nonionic	Nonionic	Nonionic	Nonionic	Ionic	Ionic	Ionic
Osmolality (Osm/kg)	22.5	25.8	23.8	16.9	21.8	16.6	22.6	23.5	N/A
Viscosity (mPa s at 37 °C)	1.96	1.35	0.63	0.78	1.39	1.11	1.97	0.89	0.70–0.95
T1 relaxivity (L/mmol s ⁻¹) blood	2.9	2.0	1.3	1.4	4.96	2.0	5.3	1.19	2.7–3.3
K_{obs} (s ⁻¹)	4.3	4.2	4.4	4.6	5.3	5.2	6.7	8.2	33.4–45.7
$T_{1/2}$	1.2×10^{-3}	2.1×10^{-5}	6.3×10^{-5}	2.0×10^{-2}	90 min	80–120 min	1.17–2.02 h		29 min
	10 min	9 h, 60 h, >1 month	3 h	35 s	18 h				

4. Osmolality

Logically, the ionic complexes have a higher osmolality than the so-called non-ionic complexes (Table 2). Non-ionic complexes with low osmolality were developed to improve tolerance and allow the use of higher doses [20,21]. Because of the low amounts of compounds injected for MR imaging, the ionic charge of the Gd complexes is not a crucial factor, as the increased plasma osmolality following administration of Gd chelates is very low, unlike what is observed with iodinated contrast media. Low osmolality chelates could be advantageous when higher doses are required. In addition, it has been shown in a rat model that the extravasation of ionic gadopentetate was associated with higher incidences of necrosis, hemorrhage and edema than non-ionic gadoteridol [22]. The first commercially available agents had a 0.5 M osmolality. Manufacturers now provide 1 M solutions (Table 2) in order to increase the quality of bolus injection and to reduce the volume of injected solution.

5. Viscosity

It is a measure of the amount of internal friction within a fluid. Increasing viscosity results in increased resistance to flow. The viscosity of water is 1 cP (centiPoise) at 20 °C, and those of plasma and whole blood are 1.5 and 3 cP at 37 °C. The viscosities of the first-generation intravenous Gd agents at 37 °C range from 1.3 to 2.9 cP, with these figures increasing by approximately 50% at room temperature [1]. At the standard doses and injection rates the viscosity of current Gd-CA is not a significant concern. However, viscosity should be taken into account when dealing with high-flow-rate applications and small catheters.

6. Dosage

The recommended dose of nonspecific gadolinium chelate for the majority of clinical indications is 0.1 mmol/kg of body weight and the recommended injection rate is 2–3 mL/s (0.5 mmol/ml). However, higher doses (0.2–0.3 mmol/kg), may also be required for MR angiography and CNS imaging (Table 1). Liver specific contrast agent gadobenate is approved for a dose of 0.05 mmol/kg while gadoxetate is approved for a dose of 25 µmol/kg. For MR angiography gadodiamide and gadopentetate are approved for a dose up to 0.3 mmol/kg, while gadoterate for a dose up to 0.2 mmol/kg. The blood pool agent gadofosveset is approved for MR angiography of the abdominal and limb vessels for a dose up to 0.03 mmol/kg.

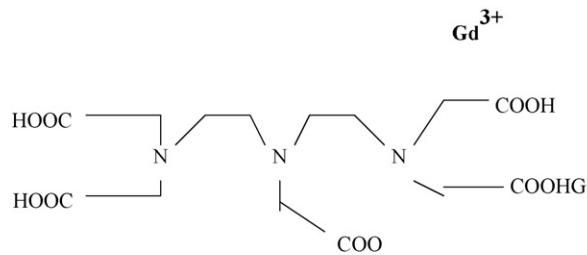
All nonspecific gadolinium chelates except gadobutrol are available in a concentration of 0.5 mmol/mL; gadobutrol is available in a concentration of 1 mmol/mL. To date, no cumulative dose beyond which NSF (or any other adverse event) may occur has been established. However, it seems that most NSF cases were reported in patients with end stage renal disease who received large amounts of gadolinium chelates as a result of serial MR examinations.

7. Mechanism of action

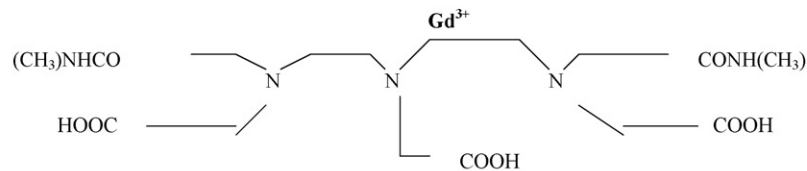
Gd-CA of small molecular weight are extracellular space markers. They are highly paramagnetic because gadolinium has seven unpaired electrons. They shorten the T₁, T₂, and T₂^{*} relaxation time constants of adjacent water protons in tissues. Furthermore, the chemical structure of the chelate also influences the number of available sites for interaction between water molecules and Gd³⁺, which conditions the paramagnetic efficacy of the contrast agents. These relaxation effects tend to produce signal enhancement on T₁-weighted MR images and

signal loss on T₂- and T₂^{*}-weighted MR images. One exception is short inversion time inversion recovery (STIR) sequences with gadolinium accumulation leading to signal loss as a result of T₁ shortening. Most applications of contrast-enhanced MRI and MRA rely on shortening of T₁ and images are acquired after a bolus injection of Gd with short repetition times (TRs) and short echo times (TEs).

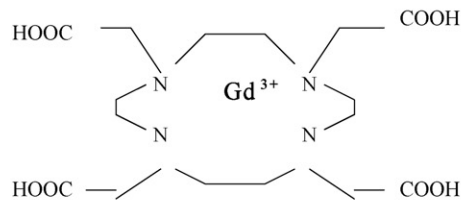
Gadobenate dimeglumine (Gd-BOPTA) is an octadentate chelate of the paramagnetic ion gadolinium, with a distribution phase followed by an elimination phase. In addition it produces transient, weak protein binding. It is distributed not



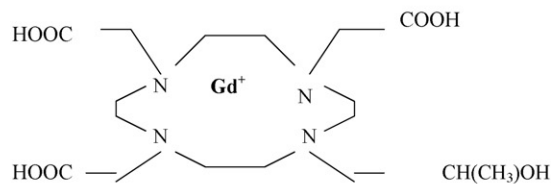
Ionic and linear Gd-DTPA (gadopentetate dimeglumine; Magnevist)



Non-ionic and linear Gd-DTPA-BMA (gadodiamide; Omniscan)

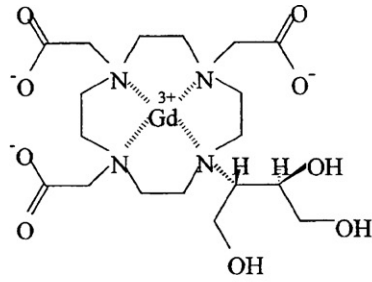


Ionic and cyclic Gd-DOTA (gadoterate meglumine; Dotarem)

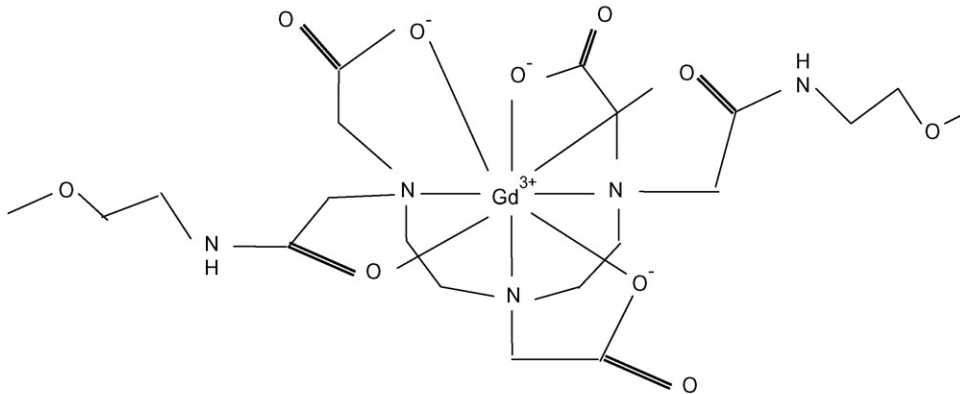
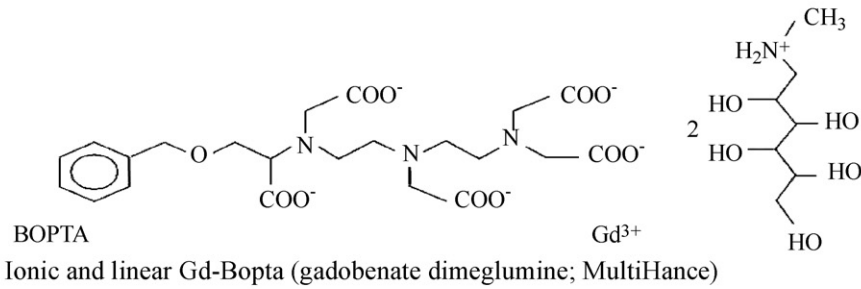


Non-ionic and cyclic Gd-HP-DO3A (gadoteridol; ProHance)

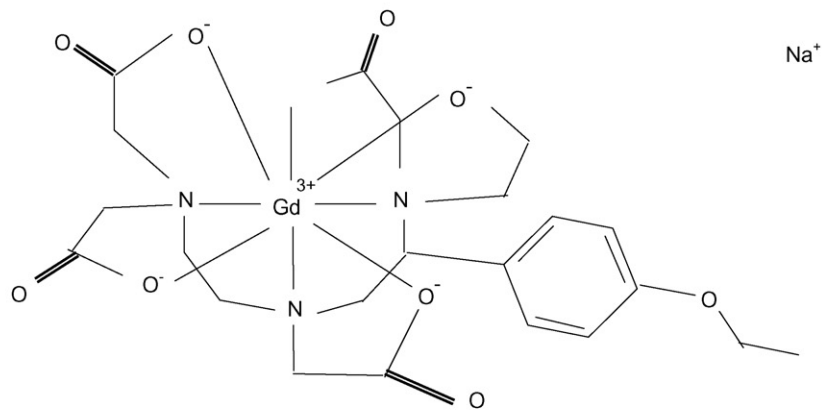
Fig. 1. Examples of the structures of the organic ligands of gadolinium chelates approved for clinical use.



Non-ionic and cyclic gadobutrol (Gadovist)



Nonionic and linear Gadoversetamide (Gd-DTPA-BMEA, OptiMARK)



Gadotexetate disodium (Gd-EOB-DTPA, Primovist in Europe, Eovistin in the USA)

Fig. 1. (Continued).

only to the extracellular space, but is also selectively taken up by functioning hepatocytes and excreted into bile by canalicular multispecific organic anion transporter shared with bilirubin. The biliary excretion rate is only 3–5% in humans, but is sufficient to bring about specific, long lasting enhancement of the normal liver parenchyma. Gd-EOB-DTPA is a paramagnetic hepatobiliary contrast agent with a non-specific extracellular phase followed by a hepatocellular uptake via the anionic-transporter protein. It is excreted almost equally by the kidneys and biliary system, while about 2% enters the enterohepatic circulation. It has a higher T1 relaxivity in human plasma than gadopentetate dimeglumine.

With these two hepatobiliary agents, post contrast imaging includes rapid dynamic T1-weighted images followed by T1-weighted delayed images.

8. Pharmacokinetics

8.1. Biodistribution

Nonspecific extracellular gadolinium chelates (gadopentate, gadoterate, gadodiamide, gadoteridol, gadobutrol) have pharmacokinetics similar to those of iodinated radiographic contrast agents and are excreted almost exclusively by passive glomerular filtration through the kidneys, without secretion nor reabsorption (elimination is complete in 24–48 h). For gadofosveset 84% of the injected dose is eliminated after 14 days. They are hydrophilic complexes that do not bind to proteins or receptors and are excreted unmetabolized in urine. Gadolinium chelates have low molecular masses (around 500 Da). Because of their small size, they are rapidly cleared from the intravascular space into the interstitial space, and therefore their biodistribution is non-specific. In patients with normal renal function about 98% of these agents are excreted within 24 h of injection. Biobistribution of four commercially available Gd-CA has been studied in mice and rats using a radiolabeling technique [23]. The macrocyclic chelates, gadoterate and gadoteridol, had the lowest residual Gd in rodents. The lowest-to-highest order of residual whole body gadolinium at 14 days was: gadoteridol \approx gadoterate = gadopentetate \ll gadodiamide [23].

Gadobenate dimeglumine (Gd-BOPTA), gadoxetic acid disodium (Gd-EOB-DTPA), and gadofosveset (Gd-DTPA) are eliminated through both the renal and hepatobiliary pathways [19,24–27]. Hepatic uptake represents 2–4% of the injected dose of gadobenate (kidney pathway: 96–98%), 50% of the injected dose of gadoxetic acid disodium (kidney pathway: 50%), and 9% of the injected dose for gadofosveset (kidney pathway: 91%).

9. Acute renal adverse reactions (contrast induced nephropathy)

The guidelines of the Safety Committee of the European Society of Urogenital Radiology indicate that, for MR examinations, the risk of nephrotoxicity is very low when Gd-CA are used in approved doses [28]. They also indicate that Gd-CA should not be used for radiographic examinations in patients with renal impairment and that for radiographic examinations,

Gd-CA are more nephrotoxic than iodinated contrast in equivalent X-ray attenuating doses. Nephrotoxicity of the Gd-CA has now been documented in both man and animals. The use of high doses (>0.3 mmol/kg bw) of Gd-CA in patients with impaired renal function is clearly contraindicated. In 2003, Sam et al. [29] reported that in 3.5% of 195 patients with abnormal creatinine clearance levels, acute renal failure developed after Gd-CA. For MR angiography the incidence was 1.9% and for digital subtraction angiography 9.5%. Dialysis was required in three of the seven patients who developed acute renal failure. The doses of gadolinium-DTPA ranged from 0.31 to 0.41 mmol/kg for MR angiography and from 0.27 to 0.42 mmol/kg for digital subtraction angiography. In an experimental study investigating whether Gd-CA were less nephrotoxic than iodine media in X-ray arteriography of a kidney made temporarily ischemic by arterial balloon occlusion, Elmståhl et al. [6] found in 2004 that 0.5 M Gd-CA were more nephrotoxic than both equal-attenuating (70 mg I/mL) and equimolar (190 mg I/mL) concentrations of the iodine media. Using the same ischemic porcine model, they found in 2007 that the histomorphological changes caused by Gd-CA were similar to those caused by iodine media [5]. Vacuolation appeared to be independent of the osmolality and viscosity of the contrast medium, and did not seem to be an indicator of renal impairment. In a retrospective study that included 473 patients with stage 3 and 4 renal failure who received 0.2 ml/kg of gadolinium contrast medium, Ergun et al. [8] found that risk factors for acute renal failure after Gd-CA included diabetic nephropathy and low GFR. In addition, Briguori et al. [3] showed in prospective study that the strategy of Gd-CA administration does not seem to reduce the rate of contrast induced nephropathy, as compared to the iodinated iso-osmolality contrast agents in patients with chronic renal insufficiency.

10. Delayed adverse reactions

This rare and devastating reaction (nephrogenic systemic fibrosis) is described in details in the following chapters.

11. Acute non-renal adverse reactions

General adverse events may be seen following injection of Gd-CA with a frequency much lower than that observed with iodinated contrast media. The most frequently reported adverse events include transient headache, nausea, and emesis [11]. Other adverse events have been observed, but at frequencies of less than 1%. The incidence of moderate and severe reactions is well below 1% [30,31]. A post marketing surveillance study [32] of 24,308 patients who were intravenously injected with gadolinium DOTA for various diagnostic examinations reported that the incidence of adverse events was 0.4%; most of them were rated as minor, such as feeling of warmth or taste alteration. Anaphylactoid reactions, involving respiratory, cardiovascular, cutaneous, gastrointestinal and/or genitourinary manifestations have been reported but are anecdotal. Their true prevalence appears to be between 1/100,000 and 1/500,000 [11]. Most patients who experienced anaphylactoid reactions had a past history of respiratory difficulties or respiratory allergic dis-

ease. In 1991, Neindorf et al. [30] reported that the risk of adverse reactions to gadopentetate dimeglumine was 3.7 times higher in patients with a prior history of reaction to iodinated contrast media. Regarding the safety of higher unapproved dosages, the number of published studies is too small to draw any conclusions.

One of the reasons for the lower prevalence of adverse reactions after Gd-CA than iodine-based contrast agents is the much lower dose of the agent used for MRI than for radiography, i.e., the molar dose for enhanced MRI of the brain is on average 8 times lower than the molar dose for CT of the brain

12. Pregnancy and lactating women

A teratogenic effect of gadolinium chelates has been documented in animal studies, but no controlled studies have been performed. In rabbits, gadolinium can be detected in the fetus the 60 min after it has been given intravenously to the mother [33]. There are relatively few clinical reports of the effects on neonates of giving gadolinium agents to the pregnant mother. Due to the lack of knowledge it is recommended that Gd-CA should be avoided in the first trimester and used later in pregnancy only when needed to establish a critical diagnosis that will significantly impact patient care [34]. In those cases a stable macrocyclic agent is recommended [13] in order to leave the smallest amount (if any) of the gadolinium ion in the fetus. Denying a clinically justified examination may cause more harm to the mother and hereby the fetus than the examination itself.

Only small amounts of gadolinium contrast media reach the milk after intravenous administration of a purely extracellular Gd-CA to the mother, less than 0.04% of the intravenous dose was excreted into the milk over 24 h according to Kubik-Huch et al. [35]. The amount transferred to a nursing infant would be more than 100 times less than the permitted IV dose (200 μ mol/kg) for neonates. Furthermore only a very small portion of the ingested agent is taken up from the gut. The Contrast Media Safety Committee of the European Society of Urogenital Radiology indicates that breast feeding may be continued normally when gadolinium agents are given to the mother [34]. Whether there is a higher transfer of the protein bound agents (the high relaxivity agents) than of the purely extracellular Gd-CA to milk remains unknown. Therefore a stability (macrocyclic) agent should be for a lactating mother.

References

- [1] Lin SP, Brown JJ. MR contrast agents: physical and pharmacologic basics. *J Magn Reson Imaging* 2007;25:884–99.
- [2] Burns M. The US market for medical imaging contrast media. Las Vegas, NV: Bio-tech Systems, Inc.; 2004.
- [3] Briguori C, Colombo A, Airoidi F, Melzi G, et al. Gadolinium-based contrast agents and nephrotoxicity in patients undergoing coronary artery procedures. *Catheter Cardiovasc Interv* 2006;67:175–80.
- [4] Grobner T, Prischl FC. Gadolinium and nephrogenic systemic fibrosis. *Kidney Int* 2007;72:260–4.
- [5] Elmstahl B, Leander P, Grant D, et al. Histomorphological changes after renal X-ray arteriography using iodine and gadolinium contrast media in an ischemic porcine model. *Acta Radiol* 2007;23:1–11.
- [6] Elmstahl B, Nyman U, Leander P, Chai CM, Frennby B, Almen T. Gadolinium contrast media are more nephrotoxic than a low osmolar iodine medium employing doses with equal X-ray attenuation in renal arteriography: an experimental study in pigs. *Acad Radiol* 2004;11:1219–28.
- [7] Elmstahl B, Nyman U, Leander P, et al. Gadolinium contrast media are more nephrotoxic than iodine media. The importance of osmolality in direct renal artery injections. *Eur Radiol* 2006;16:2712–20.
- [8] Ergun I, Keven K, Uruç I, et al. The safety of gadolinium in patients with stage 3 and 4 renal failure. *Nephrol Dial Transplant* 2006;21:697–700.
- [9] Mendichovszky IA, Marks SD, Simcock CM, Olsen OE. Gadolinium and nephrogenic systemic fibrosis: time to tighten practice. *Pediatr Radiol* 2007;(October (18)) [Epub ahead of print].
- [10] Thomsen HS, Marckmann P, Logager VB. Enhanced computed tomography or magnetic resonance imaging: a choice between contrast medium-induced nephropathy and nephrogenic systemic fibrosis? *Acta Radiol* 2007;59:3–6.
- [11] Shellock FG, Kanal E. Safety of magnetic resonance imaging contrast agents. *J Magn Reson Imaging* 1999;10:477–84.
- [12] Thomsen HS, Marckmann P, Logager V. Nephrogenic systemic fibrosis (NSF): a late adverse reaction to some of the gadolinium based contrast agents. *Cancer Imaging* 2007;7:130–7.
- [13] Thomsen HS. ESUR guideline: gadolinium-based contrast media and nephrogenic systemic fibrosis. *Eur Radiol* 2007;17:2692–6.
- [14] Idee JM, Port M, Raynal I, Schaefer M, Le Greneur S, Corot C. Clinical and biological consequences of transmetallation induced by contrast agents for magnetic resonance imaging: a review. *Fundam Clin Pharmacol* 2006;20:563–76.
- [15] Evans CH. Biochemistry of the lanthanides. New York: Plenum Press; 1990.
- [16] Gandhi SN, Brown MA, Wong JG, Aguirre DA, Sirlin CB. MR contrast agents for liver imaging: what, when, how. *RadioGraphics* 2006;26:1621–36.
- [17] Bellin MF. MR contrast agents: the old and the new. *Eur J Radiol* 2006;314–23.
- [18] Bellin MF, et al. Safety of MR liver specific contrast media. *Eur Radiol* 2005;15:1607–1614.
- [19] Rapp JH, Wolff SD, Quinn SF, et al. Aortoiliac occlusive disease in patients with known or suspected peripheral vascular disease: safety and efficacy of gadofosveset-enhanced MR angiography. Multicenter comparative phase III study. *Radiology* 2005;236:71–8.
- [20] Tweedle MF. The proHance story: the making of a novel MRI contrast agent. *Eur Radiol* 1997;7(suppl 5):S225–30.
- [21] Olukotun AY, Parker JR, Meeke MJ, Lucas MA, Fowler DR, Lucas TR. Safety of gadoteridol injection: US clinical trial experience. *J Magn Reson Imaging* 1995;5:17–25.
- [22] Cohan RH, Leder RA, Herzberg AJ, et al. Extravascular toxicity of two magnetic resonance contrast agents: preliminary experience in the rat. *Invest Radiol* 1991;26:224–6.
- [23] Tweedle MF, Wedeking P, Krishan K. Biodistribution of radiolabeled, formulated gadopentetate, gadoteridol, gadoterate, and gadodiamide in mice and rats. *Invest Radiol* 1995;30:372–80.
- [24] Kirchin MA, Pirovano GP, Spinazzi A. Gadobenate dimeglumine (Gd-BOPTA): an overview. *Invest Radiol* 1998;33:798–809.
- [25] Spinazzi A, Lorusso V, Pirovano G, Kirchin M. Safety, tolerance, biodistribution and MR imaging enhancement of the liver with Gd-BOPTA: results of clinical pharmacologic and pilot imaging studies in non-patient and patient volunteers. *Acad Radiol* 1999;6:282–91.
- [26] Hamm B, Staks T, Mühler A, et al. Phase I clinical evaluation of Gd-EOB-DTPA as a hepatobiliary MR contrast agent: safety, pharmacokinetics, and MR imaging. *Radiology* 1995;195:785–92.
- [27] Reimer P, Rummeny EJ, Shamsi K, et al. Phase II clinical evaluation of Gd-EOB-DTPA: dose, safety aspects, and pulse sequence. *Radiology* 1996;199:177–83.
- [28] Thomsen HS. How to avoid CIN: guidelines from the European Society of Urogenital Radiology. *Nephrol Dial Transplant* 2005;20(Suppl 1):i18–22.
- [29] Sam II AD, Morasch MD, Collins J, Song G, Chen R, Pereles FS. Safety of gadolinium contrast angiography in patients with chronic renal insufficiency. *J Vasc Surg* 2003;38:313–8.

- [30] Niendorf HP, Hausteijn J, Cornelius I, Alhassan A, Clauss W. Safety of gadolinium-DTPA: extended clinical experience. *Magn Reson Med* 1991;22:222–8.
- [31] Thomsen HS. Frequency of acute adverse events to a non-ionic low-osmolar contrast medium: the effect of verbal interview. *Pharmacol Toxicol* 1997;80:108–10.
- [32] Herborn CU, Honold E, Wolf M, et al. Clinical safety and diagnostic value of the gadolinium chelate gadoterate meglumine (Gd-DOTA). *Invest Radiol* 2007;42:58–62.
- [33] Novak Z, Thurmond AS, Ross PL, Jones MK, Thornburg KL, Katzberg RW. Gadolinium-DTPA transplacental transfer and distribution in fetal tissue in rabbits. *Invest Radiol* 1993;28:828–30.
- [34] Webb JA, Thomsen HS, Morcos SK. The use of iodinated and gadolinium contrast media during pregnancy and lactation. *Eur Radiol* 2005;15:1234–40.
- [35] Kubik-Huch RA, Gottstein-Aalame NM, Frenzel T, et al. Gadopentetate dimeglumine excretion into human breast milk during lactation. *Radiology* 2000;216:555–8.