

Clinical Note

Tiny Ferromagnetic Intraocular Foreign Bodies Detected by Magnetic Resonance Imaging: A Report of Two Cases

Yong Zhang, MD, Jingliang Cheng, MD, PhD,* Jie Bai, MD, Cuiping Ren, MD, Yan Zhang, MD, Xuemei Gao, MD, Xiaolin Cui, MD, and Yun Jun Yang, MD

We report two cases with tiny ferromagnetic intraocular foreign bodies (FBs) that were demonstrated only on magnetic resonance imaging (MRI) and confirmed by subsequent ophthalmologic operation. Both of the patients had a history of ocular trauma and their clinical symptoms were compatible with an intraocular FB. Plain x-ray film, 3 mm slice thickness computed tomography (CT) scans (Toshiba TXT 600 system and GERP22 system), B-scan ultrasonography, and an MRI study (Siemens Impact 1.0 MR system) were acquired. MR examinations were performed using spin-echo (SE) T1, T2, and PD-weighted axial and sagittal or coronal images with 3 mm slice thickness. Plain x-ray film, 3 mm slice thickness CT scans and B-scan ultrasonography all failed to demonstrate any tiny intraocular FBs in these two patients, whereas MRI revealed tiny ferromagnetic FBs due to their characteristic magnetic susceptibility artifact. A ferromagnetic FB was found in the vitreous body of each patient, which were $0.375 \times 0.3 \times 0.15$ mm and $0.5 \times 0.4 \times 0.2$ mm, respectively, and there was no evidence of MR-induced damage. We suggest that tiny ferromagnetic fragments with a diameter below 0.5 mm, which are too small to be visualized by x-ray plain films and CT images, may be visualized on MR images. These tiny ferromagnetic particles may not be large enough to cause ocular damage during a 1.0T MRI examination. MRI may be a useful tool in the evaluation of tiny intraocular ferromagnetic FBs if other imaging modalities such as plain s-ray, CT scan, and ultrasonography failed to do so. Further evaluation with a large-scale study (in vitro and in vivo animal study) for the safety of detecting tiny (<0.5 mm) intraocular ferromagnetic particles is warranted.

Key Words: ocular trauma; ferromagnetic intraocular foreign bodies; magnetic resonance imaging

J. Magn. Reson. Imaging 2009;29:704–707.
© 2009 Wiley-Liss, Inc.

GENERALLY, while ocular trauma patients with suspected ferromagnetic intraocular foreign bodies (FBs) have accepted magnetic resonance imaging (MRI) scanning, ferromagnetic intraocular FBs could move within the eye and cause severe ocular injury, such as hyphema and increased intraocular pressure (1–3). Therefore, MRI was not an appropriate modality for patients with ferromagnetic intraocular FBs. Clinical reports of detection and localization of ferromagnetic intraocular FBs by means of MRI were a rarity. Here we report two cases with ferromagnetic intraocular FBs detected by MRI examination without ocular injury and confirmed by ophthalmologic operation.

CASE REPORTS

Case One

A 26-year-old man suffered from eye trauma and presented with symptoms of intraocular FBs in the right eye for about 1 day. Ophthalmologic examination revealed that his right eye's visual acuity had dramatically decreased to only light perception, a marked shallowing in anterior chamber depth (ACD), opacity of lens and vitreous body, and multiple rust spots within the anterior capsule. Radiological examination disclosed that the results of plain x-ray film, computed tomography (CT; Toshiba TXT 600-type system; 3 mm slice thickness with no interslice gap) (Fig. 1A), and B-scan ultrasonography were negative. The MRI was performed on a Siemens Impact 1.0T system; routine spin-echo (SE) MR images of the eye were scanned with axial T1, T2-weighted (Fig. 1B,C), coronal T1, T2-weighted (Fig. 1D,E), and sagittal T1-weighted pulse sequences (Fig. 1F), 3-mm slice thickness and 0.1 mm interslice gap. MRI demonstrated an area of signal void and a high-signal-intensity focus at the temple side of the right eye; meanwhile, image distortion caused by magnetic susceptibility artifacts (MSAs) near the ferromagnetic FBs was also observed within the vitreous body. Two weeks later the patient had undergone magnetic conducting rod extraction in combination with vitrectomy without any kind of damage during the operation. The ophthalmologist confirmed that a $0.375 \times 0.3 \times 0.15$ mm

Department of Radiology, First Affiliated Hospital of Zhengzhou University, Zhengzhou, Henan, P.R. China.

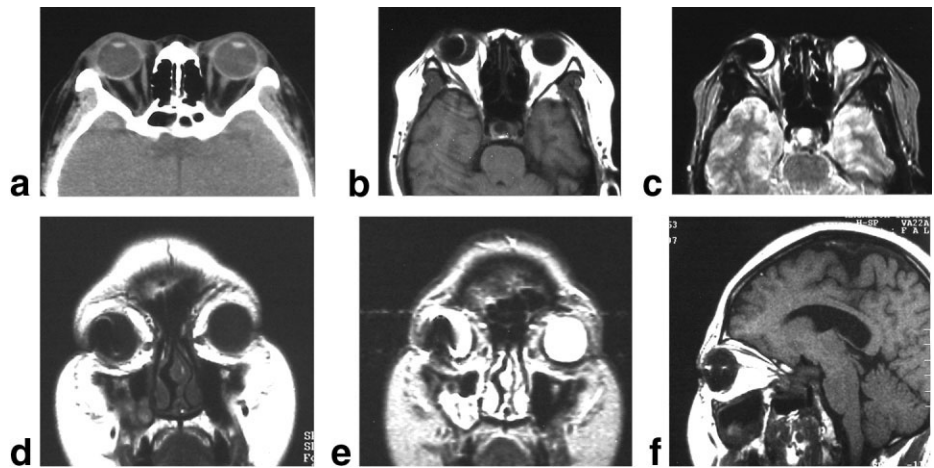
*Address reprint requests to: J.C., Department of Radiology, First Affiliated Hospital of Zhengzhou University, Jianshe Road, Zhengzhou, 450052, Henan, P.R. China. E-mail: chengjl-2008@163.com

Received May 6, 2008; Accepted September 30, 2008.

DOI 10.1002/jmri.21637

Published online in Wiley InterScience (www.interscience.wiley.com).

Figure 1. Case 1. **A:** CT image (3-mm slice thickness with no interslice gap) did not demonstrate any abnormal intensity within either side of the eyeball. 3-mm slice thickness with 0.1-mm interslice gap axial T1WI and T2WI (**B,C**), coronal T1WI and T2WI (**D,E**), and sagittal T1WI (**F**) demonstrated image distortion and centric area of signal void and a circumjacent high-signal-intensity focus at the temple side of the right eye, indicating the ferromagnetic foreign bodies within the vitreous body of the right eye.



ferromagnetic FB was located within the vitreous body and without any MR-induced damage.

Case Two

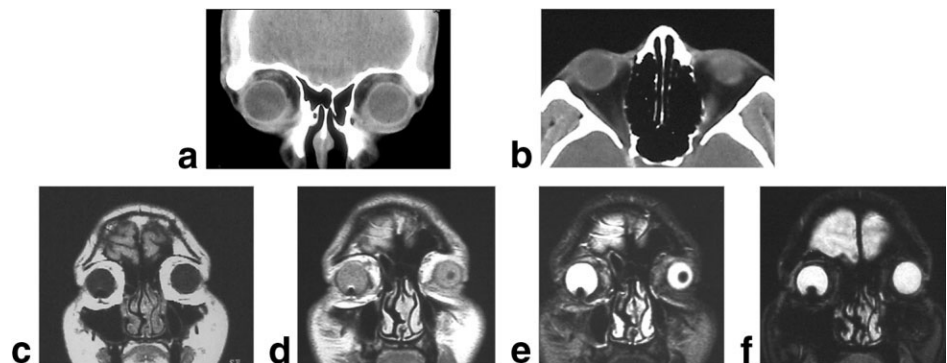
A 25-year-old male patient complained that iron particles had splashed into his right eye when he lathed a steel rod 2 days previously. He had only suffered from lacrimation and local pain and was treated with antibiotic class eye drops then and there. Ophthalmologic examination disclosed that visual acuity in his right eye was hand motion at 5 inches and he had a line-like white abrasion on the corneal at the 3 o'clock position. He also presented with lens opacity and brown rust spots in the anterior lens capsule. Radiological examination showed that the results of plain x-ray and CT were negative, whereas B-scan ultrasonography examination indicated that a FB was located at the nose side of the right body. Coronal (Fig. 2A) and axial (Fig. 2B) CT images were performed with a GE RP22-type system with 3 mm slice thickness without interslice gap. The MR images were acquired with spin-echo sequences using phased-array surface coils on a Siemens Impact 1.0T MR system. MRI of the eye was performed with T1, T2-weighted, and PD-weighted axial and coronal pulse sequences (Fig. 2C–F) with 3-mm slice thickness and 0.1 mm interslice gap. MRI demonstrated slightly local image distortion and centric area of signal void and a circumjacent high-signal-intensity focus within the vitreous body. Eleven days later the ophthalmologist per-

formed magnetic conducting rod extraction in combination with vitrectomy, during which no evidence of MR-induced damage was found, and a 0.5 × 0.4 × 0.2 mm ferromagnetic FB located in vitreous body at the 7 o'clock position was removed.

DISCUSSION

Substances with positive magnetic susceptibility are called paramagnetic, those with negative magnetic susceptibility are called diamagnetic, and those with strong positive magnetic susceptibility are called ferromagnetic (4). Ferromagnetism is frequently observed in transition elements, such as Fe, Co, and Ni; by the rare earths, Gd, Tb, Dy, Ho, Er, and Tm; and by a variety of alloys and compounds involving the transition, rare earth, and actinide elements (3,5). Iron particles are the most common intraocular ferromagnetic FBs (6,7). Not only may intraocular iron FBs have the potential for ocular toxicity, including retinal inflammation (8) and atrophy of the dependent retina from mechanical compression, but also could induce pathological changes of the retina by means of iron decomposition product (9). Both of our two cases had traumatic-cataract, vitreous body opacity, siderous bulbi within anterior capsule, and dramatically decreased visual acuity. Therefore, early diagnosis and operation were extremely important for these patients with a ferromagnetic intraocular FB. The clinical implication of our report is to yield a defi-

Figure 2. Case 2. **A,B:** CT image (3-mm slice thickness with no interslice gap) showed negative within either side of the eyeball. 3-mm slice thickness with 0.1-mm interslice gap coronal T1WI (**C**), PDWI (**D**), and T2WI (**E,F**) demonstrated image distortion and centric area of signal void and a circumjacent high-signal-intensity focus within the vitreous body of the right eye.



nite diagnosis and provide evidence for the ophthalmologist to perform magnetic extraction surgery.

Generally, plain x-ray and B-scan ultrasonography can detect large intraocular iron FBs, but do not have the capability of showing tiny intraocular iron FBs. Fortunately, those tiny intraocular iron FBs could be detected alternatively on CT images (10,11). Cao et al (12) reported that a 1-mm intraocular metal FB could be detected by CT, whereas Gaster and Duda (13) reported that CT could not accurately detect a 0.5-mm metal intraocular FB. Another report (14) reported that CT could detect a 0.4×0.25 mm iron FB, and even a $0.2 \times 0.1 \times 0.1$ mm one. In our report the intraocular iron FBs ($0.375 \times 0.3 \times 0.15$ mm and $0.5 \times 0.4 \times 0.2$ mm, respectively) were not detected by 3-mm slice thickness CT images. We hypothesized that the negative result of our CT examination may be predominantly due to the tiny size of our ferromagnetic FBs (0.016 and 0.04 mm³ respectively), since Otto et al (20) had stated that the threshold size of particle detection for CT and plain films was 0.07 mm³ and 0.12 mm³, respectively. Other possible reasons may be related to the partial-volume effect of a CT scan, and the movement of the patient's eyeball when scanning. In our cases, MSAs appeared as zones of signal void bordered by crescentic regions of high signal intensity and geometric distortions. These typical appearances of the MSA could easily lead to the diagnosis of FB. On the other hand, because the sizes of the MSAs were very small, we could easily draw the conclusion that these FBs were located within the vitreous body.

Recently, although volume-CT techniques with higher space resolution have developed dramatically, the disadvantages of radiation exposure should be considered while performing ophthalmic CT examination. Some authors (15,16) tried to find a balance between minimizing radiation exposure and detecting tiny intraocular FBs, and compared the examination time, motion artifacts, radiation exposure, and diagnostic abilities between spiral CT and conventional CT (17,18). Nowadays, the routine CT scanning standards for ophthalmic trauma is 3-mm slice thickness; therefore tiny (<3 mm) metallic intraocular FBs may be missed on CT images because of the partial volume effects. We hypothesized that the ability of MRI to detect tiny intraocular ferromagnetic FBs should be superior to plain x-ray, CT, and B-scan ultrasonography due to the characteristic MSAs caused by the intraocular tiny ferromagnetic intraocular FBs, which was proven in these two cases. We suggest that ocular trauma patients with suspected ferromagnetic intraocular FBs (for example, deposition of multiple rust spots in different tissues of eyeballs) should undergo MRI examination when the results of plain x-ray, CT, and B-scan ultrasonography are negative. MRI study can detect tiny ferromagnetic FBs, thus providing evidence for performing magnetic extraction surgery.

Several authors (1-3,20) reported that MRI can cause serious ocular damage or visual alteration attributable to movement of the FBs in patients with

ferromagnetic intraocular FBs during MRI scanning. Therefore, MRI is contraindicated if ferromagnetic FBs can be demonstrated by skull x-ray or CT. However, in the Williams et al report (19), only one of the largest ($3 \times 1 \times 1$ mm sized) ferromagnetic FBs moved under the MRI system. Seidenwurm et al (21) revealed that 5% of the MRI facilities had no orbital screening protocol, and there has almost certainly been MR exposure in thousands of patients harboring metallic FBs in which no injuries resulted. The upper bound of the 95% confidence limits for the rate of injury to the eye due to ferromagnetic FBs is less than 0.003%. In our two reported cases the ferromagnetic intraocular FBs did not move in the Siemens Impact 1.0T MR system and no ocular damage was caused during the examination. Hence, we suggest that tiny ferromagnetic fragments that are too small to be visualized by x-ray plain films and 3-mm slice CT images may not be large enough to cause ocular damage during 1.0T MRI examination. Further evaluation with a large-scale study (in vitro and in vivo animal study) to evaluate the movement and MR safety of tiny (<0.5 mm and/or different sized) intraocular ferromagnetic particles at various field strengths (such as 1.5 and 3.0T MR) is warranted.

REFERENCES

1. Ta CN, Bowman RW. Hyphema caused by a metallic intraocular foreign body during magnetic resonance imaging. *Am J Ophthalmol* 2000;129:533-534.
2. Gunenc U, Maden A, Kynak S, et al. Magnetic resonance imaging and computed tomography in the detection and localization of intraocular foreign bodies. *Doc Ophthalmol* 1992;81:369-378.
3. Lagouros PA, Langer BG, Peyman GA, et al. Magnetic resonance imaging and intraocular foreign bodies. *Arch Ophthalmol* 1987;105:551-553.
4. Arena L, Morehouse HT, Safir J. MR imaging artifacts that simulate disease: how to recognize and eliminate them. *Radiographics* 1995;15:1373-1394.
5. Sacco DC, Steiger DA, Bellon EM, et al. Artifacts caused by cosmetics in MR imaging of the head. *AJR Am J Roentgenol* 1987;148:1001-1004.
6. Ahmadi H, Sajjadi H, Azarmina M, et al. Surgical management of intraretinal foreign bodies. *Retina* 1994;14:397-403.
7. Ahmadi H, Soheilian M, Sajjadi H, et al. Vitrectomy in ocular trauma. Factors influencing final visual outcome. *Retina* 1993;13:107-113.
8. Li XM, Wang W. The role of interleukin-2 in iron powder-induced intraocular inflammation. *Zhonghua Yan Ke Za Zhi* 2005;1:141-144.
9. Yan YN, Wang MQ, Hao JL. Empirical study of retina iron rust on rabbits. *Chin Ophthalmol Res* 1993 11: 160.
10. Huang XW, Lv HB, Lan YS, et al. Comparison of the diagnostic value of four imaging examination methods in localization the lobe boundary intraocular foreign body. *Int J Ophthalmol* 2006;6:1347-1348.
11. Zhu Y, Zhang XF, Sheng YF. Combining diagnosis of IOFB and complications with multiple image-related methods. *Chin J Ophthalmol* 2003;39:520-523.
12. Cao QX, Li WH, Shen QJ, et al. CT diagnosis of intraocular foreign bodies. *J Med Imaging* 2002;12:64-65.
13. Gaster RN, Duda EE. Localization of intraocular foreign bodies by computed tomography. *Ophthalm Surg* 1980;11:25-29.
14. Ma SY. CT diagnosis of intraocular foreign bodies. *Chin J Ophthalmol* 1989;25:2.

15. Lackner B, Schmidinger G, Funovics M. Diagnosis of intraocular foreign bodies in multidetector-CT: influence of acquisition parameters on radiation dose and ability. *Rofo* 2006;178:90–95.
16. Papadopoulos A, Fotinos A, Maniatis V, et al. Assessment of intraocular foreign bodies by helical-CT multiplanar imaging. *Eur Radiol* 2001;11:502–1505.
17. Prokesch R, Lakits A, Scholda C, et al. Spiral CT and conventional CT in the preoperative imaging of intraocular metal foreign bodies. *Radiologie* 1998;38:667–673.
18. Lakits A, Prokesch R, Scholda C, et al. Multiplanar imaging in the preoperative assessment of metallic intraocular foreign bodies. Helical computed tomography versus conventional computed tomography. *Ophthalmology* 1998;105:1679–1685.
19. Williams S, Char DH, Dillon WP. Ferrous intraocular foreign bodies and magnetic resonance imaging. *Am J Ophthalmol* 1988;105:398–401.
20. Otto PM, Otto RA, Virapongse C, et al. Screening test for detection of metallic foreign objects in the orbit before magnetic resonance imaging. *Invest Radiol* 1992;27:308–311.
21. Seidenwurm DJ, McDonnell CH, Raghavan N, et al. Cost utility analysis of radiographic screening for an orbital foreign body before MR imaging. *Am J Neuroradiol* 2000;21:426–433.