

Extrusion of Eye Socket Magnetic Implant after MR Imaging: Potential Hazard to Patient with Eye Prosthesis¹

William T. C. Yuh, MD, MSEE • Michael T. Hanigan, MD • Jeffrey A. Nerad, MD
James C. Ehrhardt, PhD • Keith D. Carter, MD • Randy H. Kardon, MD • Frank G. Shellock, MD

Metallic implants or prostheses can be potentially hazardous during magnetic resonance (MR) imaging because of movement or dislodgment of the foreign object. Magnetic eye implants have been reported to exhibit strong movement when placed in water and exposed to a field of 1.5 T. The authors report a case of orbital implant extrusion possibly caused by the movement of a magnetic orbital implant during MR imaging at 0.5 T.

Index terms: Eye, 224.42, 224.46 • Magnetic resonance (MR), safety • Prostheses

JMRI 1991; 1:711-713

¹ From the Departments of Radiology (W.T.C.Y., M.T.H., J.C.E.) and Ophthalmology (J.A.N., K.D.C., R.H.K.), University of Iowa College of Medicine, 200 Hawkins Dr., Iowa City, IA 52242; and the Department of Radiology, Cedars-Sinai Medical Center, Los Angeles (F.G.S.). Received July 12, 1991; revision requested September 6; revision received and accepted September 12. **Address reprint requests to W.T.C.Y.**

© SMRI, 1991

MAGNETIC RESONANCE (MR) examinations are contraindicated for patients with metallic foreign bodies such as bullets, shrapnel, or other types of metallic fragments. The relative risk of imaging these patients depends on the ferromagnetic properties of the object; the geometry, dimensions, and mass of the object; the degree to which the object is embedded in the tissue; the static and gradient magnetic field strength of the imager; and the location of the object in relation to vital structures (1-5). The potential risks and problems associated with MR imaging of patients with metallic foreign bodies, including metallic implants, are related to the movement or dislodgment of the object, induction of electric current, heating, and artifact on the MR image (1,3,6,7). Magnetic eye implants have been reported to exhibit strong movements when placed in water and exposed to a field of 1.5 T (8). The one report of an MR imaging-related injury resulting in blindness involved a low-field-strength unit (0.35 T) (4). We report a case of orbital implant extrusion possibly caused by the movement of the magnetic orbital implant during MR imaging with a 0.5-T unit.

• CASE REPORT

An 80-year-old man with an orbital implant on the right side was referred for MR imaging of the brain. The initial request for an MR examination was denied because of possible injury to the socket. However, the request was later granted because the patient was anophthalmic and it was presumed that there would be no residual metallic object after removal of the eye prosthesis before the MR examination. The patient experienced eye pain immediately on entering the magnet (0.5 T, Picker International, Highland Heights, Ohio), and the examination was terminated after the pilot image was obtained. A

large distortion artifact caused by the presence of the implant was found on the pilot image (Fig 1), and the patient was slowly removed from the imager. A week later, the patient started to complain of discharge from the socket. An ocular examination performed 3 weeks after MR imaging revealed a partially exposed eye socket implant extruding through an open wound in the conjunctiva (Fig 2a). Attempted repair failed, and the implant was removed surgically (Fig 2b, 2c).

• DISCUSSION

The Troutman magnetic implant (Fig 2c) was commonly used from the late 1940s to the 1950s for improving cosmetic results after enucleation. This device has the combined advantages of both the completely covered spherical implant and the uncovered motility implant (9). It gives the patient less difficulty, and there is less need for prolonged postoperative care by the ophthalmologist. The disadvantages include severe postoperative discharge, a tendency toward frequent infection of the socket, and delayed extrusion or displacement of the implant, necessitating removal (28%-50%) (9).

After enucleation, this magnetic implant is permanently inserted within the vagina bulbi. The four rectus muscles are attached to the metal meshwork on the neck of the implant (Fig 2c), with the face of the implant pointing anteriorly. A small magnet is located within the face of the implant. Finally, the conjunctiva and vagina bulbi are sutured over the implant. In the conjunctival cul de sac, a removable eye prosthesis (Fig 2d, 2e) adheres, with a magnet of opposite polarity (Fig 2e), to the permanent implant by magnetic attraction through the conjunctiva. The magnetic linkage of the implant and the prosthesis provides coordinated movement with that of the normal eye. In a strong magnetic

field, the induced force from the magnet on the metallic meshwork of the implant can cause dehiscence of the implant, allowing it to extrude through the conjunctiva.

Although extrusion is one of the inherent complications of the Troutman implant, the clinical history of our patient suggests that the loss of the implant was probably related to the MR examination. Because the implant contained a small magnet and the patient experienced discomfort before the start of imaging, it seems clear that the extrusion was caused by interactions with the static magnetic field. Most currently used implants are plastic and have no metallic components; however, caution should be exercised when imaging the anophthalmic socket, especially in those elderly patients in whom enucleation was performed more than 30 years ago. ●

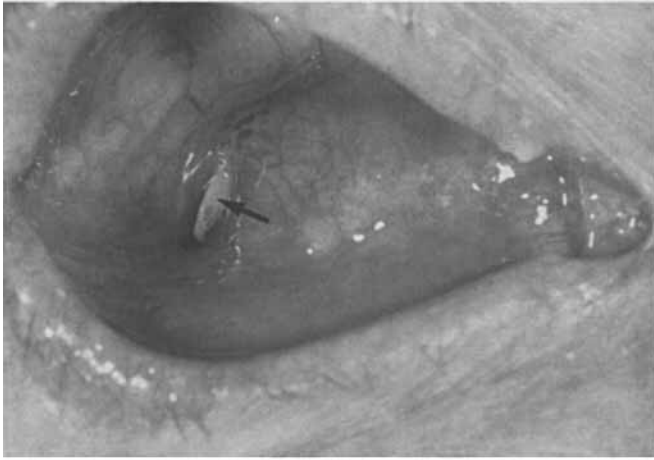
References

1. Shellock FG, Kanal E. SMRI Safety Committee. Policies, guidelines, and recommendations for MR imaging safety and patient management. *JMRI* 1991; 1:97-101.
2. Kanal E, Shellock FG, Talagala L. Safety considerations in MR imaging. *Radiology* 1990; 176:593-606.
3. Shellock FG. Biological effects and safety aspects of magnetic resonance imaging. *Magn Reson Q* 1989; 5:243-261.
4. Kelly WM, Pagle PG, Pearson A, San Diego AG, Solomon MA. Ferromagnetism of intraocular foreign body causes unilateral blindness after MR study. *AJNR* 1986; 7:243-245.
5. Teitelbaum GP, Yee CA, Van Horn DD, Kim HS, Colletti PM. Metallic ballistic

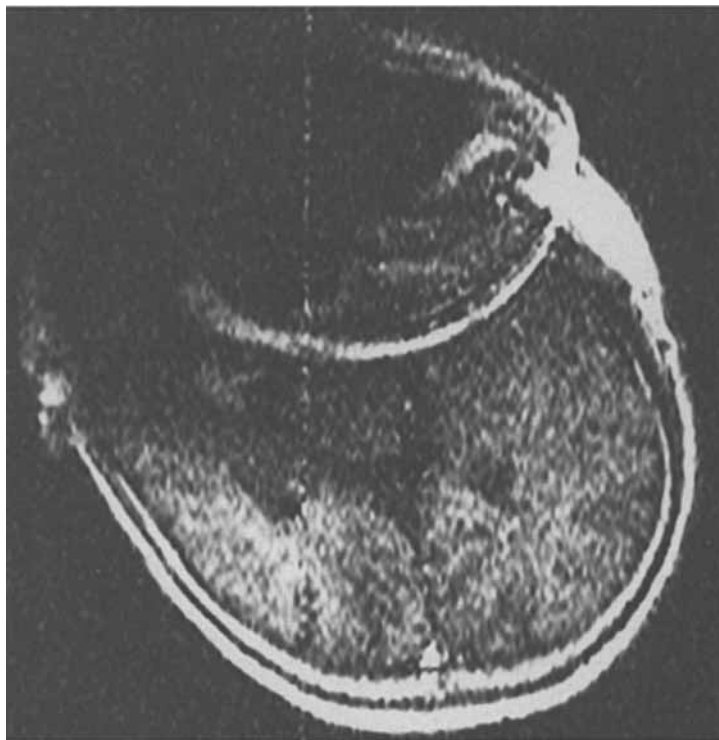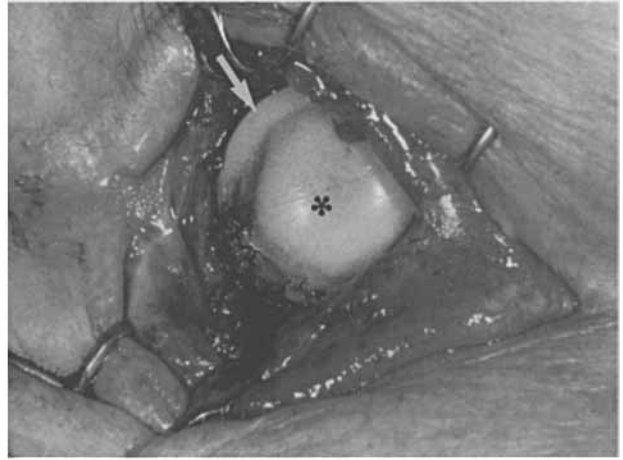


Figure 1. Pilot image of head shows large distortion artifact caused by the presence of the implant.

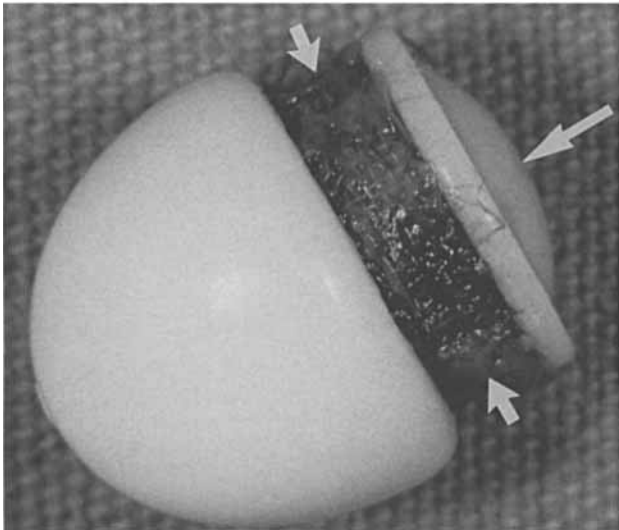
- | | |
|---|---|
| <ol style="list-style-type: none"> 6. Pusey E, Lufkin RB, Brown RKJ, et al. Magnetic resonance imaging artifacts: mechanisms and clinical significance. <i>RadioGraphics</i> 1986; 6:891-911. 7. Shellock FG. MR imaging of metallic implants and materials: a compilation of | <ol style="list-style-type: none"> fragments: MR imaging safety and artifacts. <i>Radiology</i> 1990; 175:855-859. the literature. <i>AJR</i> 1988; 151:811-814. 8. Power W, Collum LMT. Magnetic resonance imaging and magnetic eye implants (letter). <i>Lancet</i> 1988; 2:227. 9. Troutman RC. Five-year survey on use of a magnetic implant for improving cosmetic result of enucleation. <i>Arch Ophthalmol</i> 1954; 52:58-62. |
|---|---|



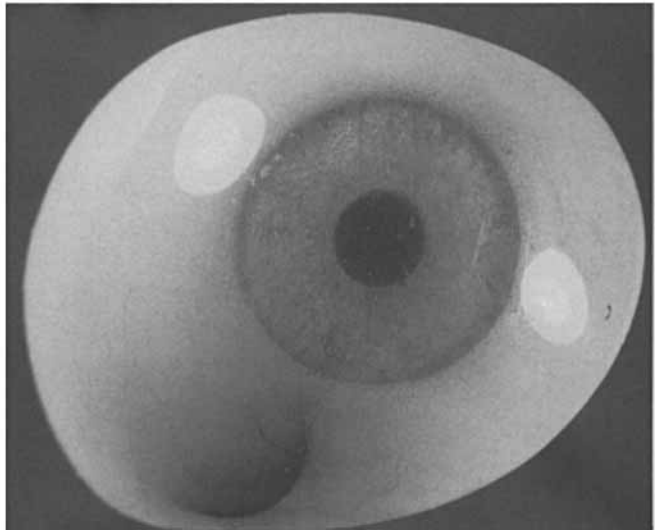
a.



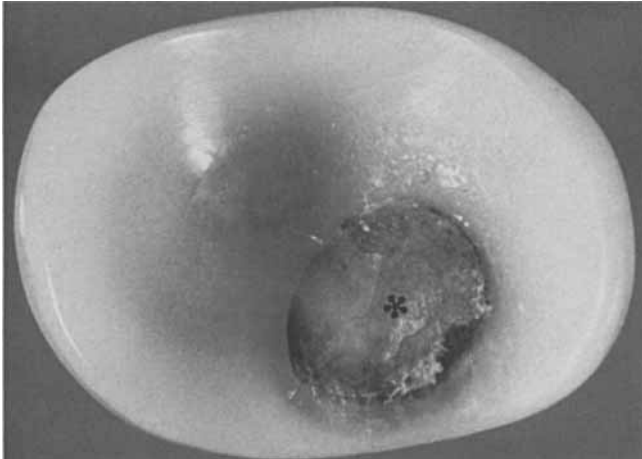
b.



c.



d.



e.

Figure 2. (a) Preoperative photograph of the right eye socket shows the implant (arrow) partially extruded through a perforation in the conjunctiva. (b) Intraoperative photograph shows the partially exposed face (*) and neck (arrow) of the implant. (c) The removed Troutman implant has a small magnet embedded beneath its face (long arrow). The metal meshwork of the neck (short arrows) provides the attachment for the four rectus muscles to coordinate the movement of the prosthesis with that of the normal eye. (d, e) Anterior (d) and posterior (e) views of the eye prosthesis show a small, posteriorly located magnet (*) that provides the force attaching the prosthesis to the magnetic implant.